

PAPER • OPEN ACCESS

Effects of Moringa (*Moringa oleifera*) leaf extract on alveolar diameter of breastfeeding and weight of infant Wistar rats

To cite this article: Neliza Utary *et al* 2019 *J. Phys.: Conf. Ser.* **1246** 012067

View the [article online](#) for updates and enhancements.

You may also like

- [Strontium biokinetic model for the lactating woman and transfer to breast milk: application to Techa River studies](#)
N B Shagina, E I Tolstykh, T P Fell *et al.*
- [The Community Health Volunteers description in Exclusive Breastfeeding Promotion and Improved Knowledge Through Training Based on The Concept of "Insufficient Milk Supply"](#)
A. Kartikasari, M. Dwi Anggraeni, L. Latifah *et al.*
- [The association between postpartum depression and air pollution during pregnancy and postpartum period: a national population study in Taiwan](#)
Ping Shih, Chih-Da Wu, Tung-liang Chiang *et al.*

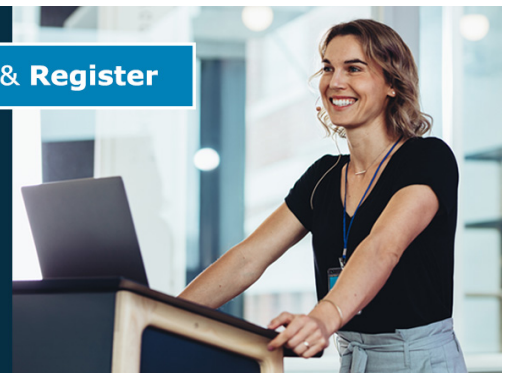

243rd Meeting with SOFC-XVIII

Boston, MA • May 28 – June 2, 2023

Accelerate scientific discovery!

Learn More & Register



Effects of *Moringa (Moringa oleifera)* leaf extract on alveolar diameter of breastfeeding and weight of infant Wistar rats

Neliza Utary¹, Krisna Murti², Indri Seta Septadina^{3*}

¹ Biomedical Sciences Program, Faculty of Medicine, Universitas Sriwijaya, Palembang, Indonesia

² Department of Anatomical Pathology, Faculty of Medicine, Universitas Sriwijaya, Palembang, Indonesia

³ Department of Anatomy, Faculty of Medicine, Universitas Sriwijaya, Palembang, Indonesia

E-mail : nelizautary66@gmail.com

Abstract. Birthweight is the quality of maternal nutrition during pregnancy. In 2005, more than 20 million infants in the world (15.5% of all births) experienced low birth weight. Efforts to improve the survival of infants. *Moringa oleifera* leaf extract is a medicinal plant that plays roles to increase mother's milk production. Determine the effect of *Moringa* leaf extracts supplementation to mamma alveolar diameter of breastfeeding maternal and weight of infant Wistar rat. This was a Completely Randomized Design, conducted in October-March 2018. The sample used were 24 pregnant rats, negative control (KN) given aquadest, positive control (KP+) Moloco 0.13 mg/g BW/day, treatment group I (KPI) dose 0,042 mole leaf extract and treatment group II (KPII) dose 0,168 mg/g BW/day. Data were analysed using ANOVA test 5% significance and continued by post hoc LSD (Least Significant Difference) test on SPSS program version 16. The results showed that in KPII, it was found that the increase of breast alveolar diameter and infants birth weight was higher than the other treatment groups. Infants weight gain is no difference between groups. *Moringa* leaf extracts to 14 effective periods of pregnancy to increase the size of an alveolar diameter of breast gland and birthweight in infants.

1. Introduction

Birthweight is the quality of the mother's nutritional state during pregnancy. In 2005, more than 20 million babies in the world (15.5% of all births) had low birth weight (LBW) with birth weight \leq 2.500 grams and 95% of which occurred in developing countries [1]. Efforts to improve the baby's survival are by exclusive breastfeeding for 6 months [2]. However, breastfeeding rates are still very low. This is assessed from data acquisition of approximately 40% of children under 6 months of age exclusively breastfed and 49% of children breastfed to 2 years of age during the last decade [3,4]. There are only 47 countries in the world that have an increase in average coverage of exclusive breastfeeding from 34% in 2000-2007 to 41% in 2008-2012 [5]. Breast milk is very beneficial for both mother and baby. In the mother may reduce the risk of postpartum haemorrhage, breast cancer, and can be used as a means of natural contraception (MAL) or pregnancy delay. Whereas in infants can be an effort to improve the welfare of infant life such as reducing morbidity and mortality caused by infection [6,7]. Breast milk is the result of mechanical stimulation of hormonal and nervous factors. One of the hormones that affect it is the hormone estrogen and progesterone. Estrogen hormones cause



hypertrophy of the ductal system and the hormone progesterone serves to increase the breast cells in the breast, stimulating the formation of casein, lactalbumin, and lactoglobulin [8].

The production and discharge of milk are affected by the hormone prolactin and the hormone oxytocin that can stimulate the number of new alveoli formation. The process of formation of new alveoli is caused by suction of breast milk at the beginning of lactation [9]. Breastfeeding mothers need sufficient nutritional intake because at the time because at the time of giving birth mother's blood and about 50% of foetal iron requirement comes from the mother. Iron from breast milk is entirely absorbed by infants [10]. There are some plants that are believed to have been used for a long time to improve the quality and quantity of breast milk, for example, leaf katuk (*Sauropus androgynus*), klabet (*Trigonella graecum* L.), and wake-up leaves (*Coleus amboinicus*), and Moringa leaf (*Moringa oleifera*) [10]. Moringa plant in Indonesia is a local plant containing phytosterol compounds (sterols) belonging to a group of steroid compounds, the high nutritional value that can be developed into food additives in breastfeeding mothers to accelerate milk production [10,11]. High phytosterol compounds consist of stigmasterol, sitosterol, and cholesterol which are hormone precursors. These compounds increase estrogen production, which stimulates the development of breast milk glands to produce milk [12]. The number of nutrients contained in the leaves of Moringa is very complete ranging from carbohydrates, proteins, fats, vitamins, and minerals. The content of Moringa leaf extract is rich in nutrients specific such as vitamin A, vitamin D, iron, folic acid, vitamin B12, zinc, and glucose [13, 14]. The aim of this study is determining the effect of Moringa leaf extract on the diameter of breast maternal breast alveolar and body weight of Wistar rats.

2. Methods

This research is a Randomized Complete Randomized Design (RAL), conducted in October 2017-March 2018 in Laboratory of Medical Biology Division, Faculty of Medicine, University of Sriwijaya, and in Pathology Anatomy Laboratory of Barokah Palembang. The sample used was 24 female pregnant mice aged 8-10 weeks who were cut off by mating with Wistar male rats (3 female mice and 1 male rat). Mice bunting the first day, weight 150-210 grams. This animal was obtained from ITB Bandung. Consisting of 4 groups (6 heads / treatment group), ie negative control (KN) given Saddest, positive control (KP+) got Moloco 0.13 mg/g BW/day, treatment group I (KPI) got leaf extract kelor 0,042 and group of treatment II (KPII) got 0,168 mg/g BW/day.

Conducting a vaginal smear to detect pregnancy by labelling the test animal identity on a cleansed object glass using 70% alcohol, inserting a suction pipette tip containing 0.9% NaCl solution into the vagina of the rat as deep as ± 2 mm, sprayed and inhaled (2 -3x). Next, spray the sucked liquid on the glass of the object, covered with an object glass cover and observed on a microscope with strong magnification. Preparation of the extract by maceration. 500 gr of *Simplicia* powder mixed with 96% ethanol (1 liter) solvent was put into the jar, closed and left for 3 days protected from sunlight. Then the mixture was filtered with filter paper, so it got Maserati. The mixture or macerate is re-macerated with the same procedure until the macerate is obtained. Then, evaporated using "vacuum rotary" evaporator to obtain a thick extract. The condensed extract is dried oven at 60 ° C. The extracts were weighed on an analytical scale and stored in a closed glass container before being used for testing [15]. In all groups were given oral treatment using gastric sonde equipped with a dulled needle (cannula) with a predetermined does not to exceed the gastric capacity of rats. Moringa leaf extract was started when the mother of pregnant rats 14 days daily at 09.00 - 10.00 am. On the first and second day, post-partum of extract after the parent is separated from her children, considering the children of this mouse is still too small and possibly can make stress mother and mouse child. Then on the third day until the seventh giving extraction done without separating the parent from her children, the giving is done at noon at around 13.00 - 16.00 with the consideration of the rat's children have finished breastfeeding and breast milk has been absorbed by the body of children of mice.

The data obtained to determine the effect of *Moringa oleifera* leaf extract on the diameter of the rat breast parent alveolus and the weight of rat Wistar breeding mice can be known through several stages of observation. Observation of the weight of a mouse child begins after the mother mouse mice get treatment every day. Observations were made at 2-day time intervals, ie: On days 1, 3, 5, and 7, when the mice were left with the mother for breastfeeding. Furthermore, the measurement of mouse body weight was done by using analytical scales. After weighing from day 1 to day 7, the overall data obtained is the amount of weight of a mouse child after suckling every day. Then on the 8th day, the

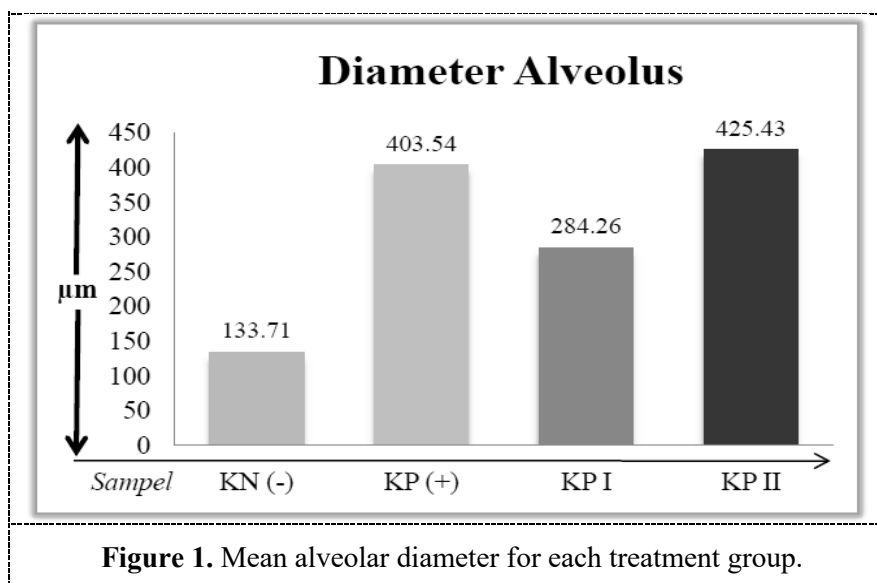
mice are separated from the mother. After that, as many as 24 rats and mice were drugged and killed. Then dissected to take the breast gland at the inguinal location to the right, while the rat is sacrificed.

After breast removal, breast tissue is fixed by histologic preparation and is saturated with Hematoxylin-Eosin staining. The calculation of the diameter of the breast gland alveolus was done through the observation of histologic preparations using a light microscope with 400 times magnification (10 X 40) to calculate the longest and widest size of the alveolar diameter. Each preparation was counted as 10 randomly-shaped alveoli (round-oval) and then calculated on average using Free-Software Image-J in image analysis and μm size unit. Image-J is a free software for Java-based digital image processing created by Wayne Rasband from Research Services Branch, National Institute of Mental Health, Bethesda, Maryland, USA [16] The use of images with Image-J in digital image analysis has been widely used in health and biology [17]

Data obtained in this study were obtained by single variance analysis (ANOVA) at 5% significance level. The dose conformity test between the extracts was done with post Hoc Test. Then this result continued with an advanced test using Least Significant Difference (LSD) and Games-Howell at the same level of significance ie 5%. The test was processed using SPSS for Windows 16 series.

3. Results

Based on the result of diameter alveolus mouse measurement in (figure 1) above, it was found that the mean of rat parent alveolus in the negative control group ($133,71 + 48,13$) μm with minimum diameter 99,60 and maximum diameter 228,92. In the positive control group, the mean was obtained ($403,54 + 52,42$) μm with minimum diameter 353,90 and maximum diameter 473,72. While from a group of treatment I got mean equal to ($284,26 + 64,95$) μm with minimum diameter 188,46 and maximum diameter 346,52. Furthermore, in the treatment group II, the mean was obtained ($425,43 + 70,08$) μm with a minimum diameter of 303,38 and maximum diameter 503,96.



Subsequently, differences in alveolar microscopy of the alveolar group extract of moringa leaf extract at doses of 0.168 mg/g BW/day with 2 weeks (14 days) appear to increase the production of breast milk that can be seen in the alveolus image showing a wider diameter of the asinus diameter compared to other groups. Moringa leaf extract with a dose of 0,042 mg/g BW/day actually has a good enough effect to increase the diameter of alveoli although not yet as high as the addition of alveoli diameter as in positive control group. Differences in the size and shape of inter-group alveoli are shown in the figure below (figure 2).

The glandular epithelium has a slightly different shape from one another depending on the condition of the secretion. If the new secretion is formed then the epithelium looks slightly elongated with the nucleus located in the basal and the secretion will appear on the apical cytoplasm (figure 4.2.KP red arrow). If the secretion has been expelled into the lumen then the oval or cuboid epithelial cell form and on the cytoplasm, there are no more secretions (Figure 4.2.KPI green arrow). The

proliferation of epithelial cells that make up the alveolus causes the size of the alveolar lumen to be enlarged. In the negative control group (Figure 4.2.KN), the alveoli appear to vary in size from the smallest size to large, oval-shaped, containing a small amount of milk. In contrast to what can be seen in the positive control group (figure 4.2.KP), in this group each lobule contains alveoli mostly widened and contains a lot of breastmilk, looks not perfectly round but round-oval. In the treatment group I (Figure 4.2.KPI), it appears that each lobule contains a slightly larger oval-shaped alveolus, containing a small amount of milk. While in the treatment group II, it was seen that each lobule contained alveoli which mostly widened contains a lot of breastmilk and did not look perfectly round but round oval (figure 4.2.KPII). Measurements of mouse body weight on the 1st, 3rd, 5th, and 7th day, the increase is presented in the figure below (figure 3).

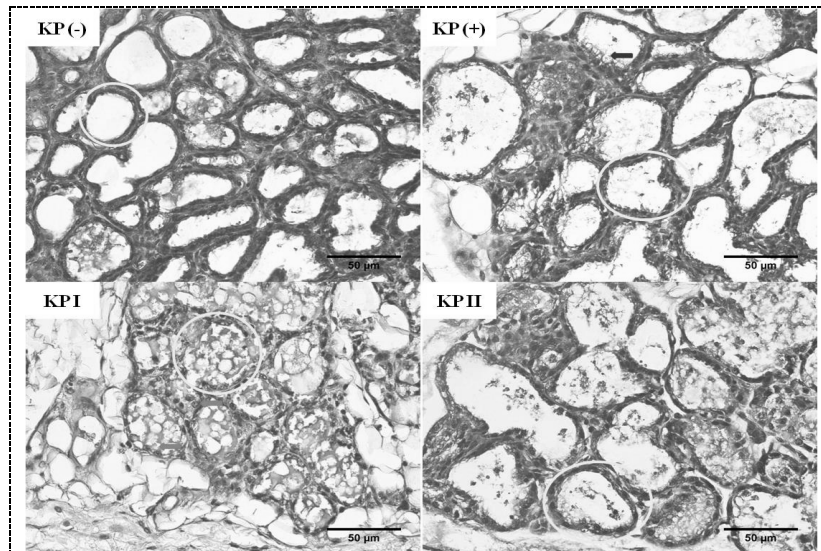


Figure 2. Alveolar description of the whole group.

Based on the result of mouse body weight measurement in (figure 3) above, it was found that the mean of mouse body weight on day 1 was negative control group ($5,23 + 0,52$) gram with minimum weight 4,50 and maximal weight 6.00. In the positive control group, the mean was obtained ($5,01 + 0,51$) gram with a minimum weight of 4.40 and maximum weight of 5.70. From the treatment group I, the average was ($5,36 + 0,35$) gram with a minimum weight of 5,00 and maximum weight 5,90. Furthermore, in the second treatment group, the mean ($6,25 + 0,42$) gram with a minimum weight of 5.80 and a maximum weight of 6.90 was obtained.

The result of rat body weight measurement was found that the mean of mouse body weight on the 3rd day was negative control group ($6,46 + 0,42$) gram with a minimum weight of 6.00 and maximum weight of 7.00. In the positive control group, the mean was obtained ($6,53 + 0,77$) gram with a minimum weight of 5,40 and maximum weight 7,50. From a group of treatment, I got average equal to ($6,78 + 0,58$) gram with minimum weight 6,30 and max weight 7,90. And the treatment group II got mean equal to ($7,91 + 0,76$) gram with minimum weight 7,00 and maximum weight 9,00.

From the result of rat body weight measurement, it was found that the mean of mouse body weight on the 5th day was negative control group ($8,00 + 0,67$) gram with minimum weight 7,10 and maximum weight 8,80. In the positive control group, the mean ($8,58 + 1,19$) gram was obtained with a minimum weight of 7.10 and a maximum weight of 10.00. From the treatment group I, the average was ($8,45 + 0,32$) gram with a minimum weight of 8,00 and maximum weight 9,00. In the treatment group II, the mean was ($9,98 + 1,09$) gram with minimum weight 8,60 and maximum weight 11,30.

The glandular epithelium has a slightly different shape from one another depending on the condition of the secretion. If the new secretion is formed then the epithelium looks slightly elongated with the nucleus located in the basal and the secretion will appear on the apical cytoplasm (figure 4.2.KP red arrow). If the secretion has been expelled into the lumen then the oval or cuboid epithelial cell form and on the cytoplasm, there are no more secretions (Figure 4.2.KPI green arrow). The proliferation of epithelial cells that make up the alveolus causes the size of the alveolar lumen to be

enlarged. In the negative control group (Figure 4.2.KN), the alveoli appear to vary in size from the smallest size to large, oval-shaped, containing a small amount of milk. In contrast to what can be seen in the positive control group (figure 4.2.KP), in this group each lobule contains alveoli mostly widened and contains a lot of breastmilk, looks not perfectly round but round-oval. In the treatment group I (Figure 4.2.KPI), it appears that each lobule contains a slightly larger oval-shaped alveolus, containing a small amount of milk. While in the treatment group II, it was seen that each lobule contained alveoli which mostly widened contains a lot of breastmilk and did not look perfectly round but round oval (figure 4.2.KPII). Measurements of mouse body weight on the 1st, 3rd, 5th, and 7th day, the increase is presented in the figure below (figure 3).

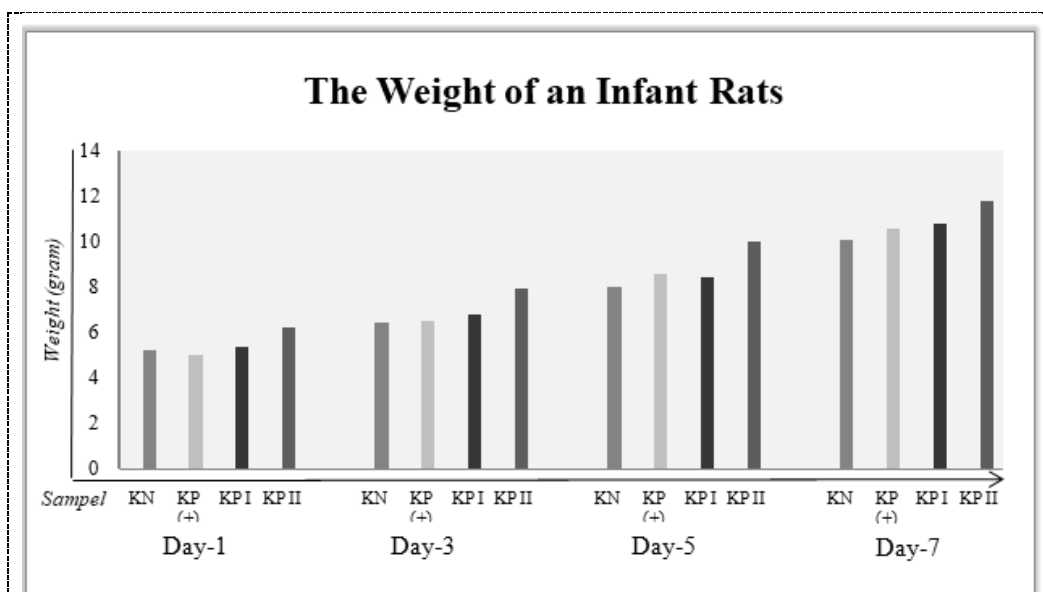


Figure 3. Mean weight of Wistar strain rat rats on ANOVA test among treatment groups.

As can be seen in figure 3, there was a significant difference in birth weight of rat children in the treatment group II compared with the other groups. Moringa leaf extract with a dose of 0.168 mg / g BW/hr proved to affect the birth weight of a mouse child. The mean birth weight was in the treatment group II (6.2) gram. While in the treatment group I obtained the average birth weight (5.3) grams. In the negative control group, there was a mean birth weight (5.2) gram, and the group from the positive control group obtained mean birth weight (5) gram. It can be seen also that the average weight gain of rat boys in the whole group did not seem much different even though there was little variation. What is interesting is the birth weight of a mouse child in the second treatment group that is on average larger than the other group. Even on the fifth day the weight of a rat boy from this group almost equalled the weight of a mouse child on the seventh day of the other three groups (table 1).

Table 1. Increased birth weight between groups.

Group	Average Wight (gram)			
	Day-1	Day-3	Day-5	Day-7
KN	5,2	6,5	8	10
KP	5	6,5	8,6	10,6
III	5,3	6,8	8,4	10,8
IV	6,2	7,9	10	11,8

In ANOVA test result to see meaning of an alveolar diameter of breast gland among all treatment group got acquisition with value $p=0,000$ ($p \leq 0,05$). This proves that the extract of morph leaf has an effect in increasing the average size of breast maternal alveolar diameter of breastfeeding mice with the highest yield in the treatment group II. Based on the posthoc test between the treatment groups, there were significant differences between negative control group and positive control group ($p \leq$

0.000), treatment group I ($p \leq 0,000$), and treatment group II ($p \leq 0,000$). In the positive control group with treatment group I also showed a significant difference ($p \leq 0,002$), and treatment group I with treatment group II ($p \leq 0,001$). While in the positive control group with treatment group II dose of Moringa leaf extract showed no significant difference ($p \geq 0.532$).

Furthermore, there was an increase in the mean of Wistar strain weight in all groups of days 1, 3, 5, and 7. On the 1st day, $p = 0.001$ ($p = 0.05$), day 3 = 0.003 ($p \leq 0.05$), and the 5th day $p = 0.006$ ($p \leq 0.05$). This proved that the extract of morph leaf had an effect on increasing the mean of Wistar strain on the 1st, 3rd, and 5th day of mice with the highest yield in the treatment group II using posthoc (Least Significant Difference). However, on the 7th day obtained the acquisition value $p = 0,094$ ($p \geq 0,05$). This proved that Moringa leaf extract had no effect in increasing the mean of body weight of Wistar strain rat on the 7th day with the highest yield in treatment group II. by using advanced test (posthoc) ie Games-Howell. Each was obtained from the same level of significance of 5% and was processed using SPSS for Windows 16 series. The posthoc test between the treatment groups on the 7th day showed that there was no significant difference between the negative control group and positive control group ($p \geq 0.833$), treatment group I ($p \geq 0.134$), and treatment group II ($p \geq 0.122$). In the positive control group with treatment group I there was no significant difference ($p \geq 0,990$) and treatment group II ($p \geq 0,557$). Furthermore, in the treatment group I with treatment group II there was also no significant difference ($p \geq 0.481$).

4. Discussions

In this study, the result of the measurement of rat breast alveolar diameter in various groups showed that the mean diameter of rat parent alveolus in treatment group II got the highest number compared to the other group ($425,43 \pm 70,08 \mu\text{m}$ with range 303,38-503,96). Statistically, there was a significant difference in mean of alveolus diameter of treatment group II with negative control group and treatment group I, but there was no significant difference with the positive control group. While treatment group I with a dose of leaf extract dose 0,042 mg/g BW/day obtained mean of alveoli diameter higher than a negative control group. This suggests that Moringa leaf extract at doses of 0.042 mg/g BW/day has a positive effect on increasing the diameter of the rat breast alveolar gland. Our data show that the effect of Moringa leaf extract depends on the quantity in the consumption of maternal mice. Moringa leaf extract dose 0,042 mg/g BW/day seems to be enough effect on the proliferation of epithelial cells of breast alveolar coat of female rats so that the majority of alveoli become bigger, thus milk production is expected to be more [18].

While the results of observations on birth weight of rat children in this study showed that the mice born from the parent group of treatment II had an ideal birth weight of 6.2 grams compared with rats from other groups. This may indicate the adequacy of nutrients in Moringa leaf extract needed by pregnant rats to meet the nutritional needs of the foetus while in the womb is much better than when given Moloco. Moringa leaf extract at a dose of 0.168 mg/g BW/day was shown to have a better effect on the birth weight of the rats than the dose that was 4 times lower as in the treatment group I because the rat boy from the treatment group I had a birth weight that has not differed considerably as a rat boy from a negative control group, and a positive control group. However, the birth weight of rat children from these three groups had normal birth weight. Moringa leaf extract with a dose of 0.042 mg/g BW/day has shown a good birth weight, although not as good as dose 0.168 mg/g BW/day.

In this case, it is expected that adequate dosage of Moringa leaf extract can prevent low birth weight if administered to pregnant women, at least in the second trimester, just as in this study of Moringa leaf extract at week 2, the 14th day of pregnancy. Besides that, a previous study [19] found that pregnant women who consumed Moringa leaf powder, the majority (> 90%) of them gave birth to children weighing over 3 kg and no births died. The findings obtained study showed similar results [12]. This is possible because the content of iron and vitamin C in Moringa leaf extract in quantity and quality enough to prevent anemia in pregnant mother mice. Moringa is a food that has many nutrients. All parts of the plant can be consumed by eating directly or processed [19,20]. The leaves contain lots of iron and proteins that are essential for consumption both for pregnant and lactating women [21]. In the powder of Moringa leaves contain protein content of 27.1/100 grams and iron as much as 28.2/100 grams [20]. In addition, Moringa leaf extract also contains many important nutrients such as calcium, vitamin A, antioxidants, complete essential amino acids, omega 3 and 6 fatty acids, beta-carotene and other compounds [19-24] which are indispensable to mammals including mother mothers during

pregnancy. Parent nutrient-ridden mice will produce a fetus who later was born as a child with enough weight [19]. Leaf extract of Moringa on broodstock mice get the slightly different result that is an increase of body weight and body length of rat rod from mother which given morrow although not significant [20].

However, the results of observations on the weight gain of rat children from all groups showed a number that did not differ greatly. This fact is incompatible with milk production which may be more than enough by the mice of this treatment group II. Given a significant difference between the diameter of the alveoli in the treatment group II compared to the other group, it means that the production of breast milk is optimally possible with optimal nutrient content as well. Thus, the weight gain of rat boys from treatment groups I and II from day to day should show a higher increase than positive controls. There is a possibility of errors in the process of breastfeeding these mice, namely the technique of breastfeeding. Or other possibilities such as the ability of a mouse child in the average breastfeeding consumption are the same, so that although high mothers' milk production may be higher in the treatment group II and more than that produced by the control group but not entirely in consumption by the mice.

5. Conclusions

From the results of this study, it can be concluded that there is a significant effect on the administration of Moringa leaf extract to the diameter of the alveolar glands of the breast of breastfeeding mice and the birth weight of rats of Wistar rats.

6. References

- [1] Kawai K, Spiegelman D, Shankar A H and Fawzi W W 2011 Maternal multiple micronutrient supplementation and pregnancy outcomes in developing countries: meta-analysis and meta-regression *Bull. World Health Organ.* **89** 402–11
- [2] Organization W H 2011 Statement: Exclusive breastfeeding for six months best for babies everywhere *World Heal. Organ. Geneva*. Retrieved from <http://www.who.int/en>
- [3] Organization W H and UNICEF 2014 Global nutrition targets 2025: Breastfeeding policy brief (WHO/NMH/NHD/14.7) *Geneva, Switz. World Heal. Organ.*
- [4] Sinha B, Chowdhury R, Sankar M J, Martines J, Taneja S, Mazumder S, Rollins N, Bahl R and Bhandari N 2015 Interventions to improve breastfeeding outcomes: a systematic review and meta-analysis *Acta Paediatr.* **104** 114–34
- [5] Requejo J, Bryce J and Victora C 2014 Fulfilling the health agenda for women and children: the 2014 report. Conference draft.
- [6] Marmi R 2015 Asuhan neonatus, bayi, balita, dan anak prasekolah *Yogyakarta: Pustaka Pelajar*. pp 25-30
- [7] Shetty P 2014 Indonesia's breastfeeding challenge is echoed the world over *World Heal. Organ. Bull. World Heal. Organ.* **92** 234
- [8] Fang H, Tong W, Shi L M, Blair R, Perkins R, Branham W, Hass B S, Xie Q, Dial S L and Moland C L 2001 Structure– activity relationships for a large diverse set of natural, synthetic, and environmental estrogens *Chem. Res. Toxicol.* **14** 280–94
- [9] Lollivier V, Marnet P, Delpal S, Rainteau D, Achard C, Rabot A and Ollivier-Bousquet M 2006 Oxytocin stimulates secretory processes in lactating rabbit mammary epithelial cells *J. Physiol.* **570** 125–40
- [10] Kristina N N and Syahisusetyd S F 2014 Pemanfaatan Tanaman Kelor (*Moringa oleifera*) Untuk Meningkatkan Produksi Air Susu Ibu *War. Penelit. dan Pengemb. Tanam. Ind.* **20** 26–9
- [11] Raguindin P F N, Dans L F and King J F 2014 *Moringa oleifera* as a Galactagogue *Breastfeed. Med.* **9** 323–4
- [12] Titi M K, Harijono E T and Endang S W 2013 Effect lactagogue moringa leaves (*Moringa oleifera* Lam) powder in rats white female wistar *J. Basic Appl. Sci. Res.* **3** 430–4
- [13] Bohnsack B L and Hirschi K K 2004 Nutrient regulation of cell cycle progression *Annu. Rev. Nutr.* **24** 433–53

- [14] Yanagida M, Ikai N, Shimanuki M and Sajiki K 2011 Nutrient limitations alter cell division control and chromosome segregation through growth-related kinases and phosphatases *Phil. Trans. R. Soc. B* **366** 3508–20
- [15] Putra I, Dharmayudha A A G O and Sudimartini L M 2016 Identifikasi Senyawa Kimia Ekstrak Etanol Daun Kelor (*Moringa oleifera* L) di Bali *J. Indones. Med. Veterinus* **5** 464–73
- [16] Podlasov A and Ageenko E 2003 Working and Development with ImageJ: A Student Reference *Dep. Comput. Sci. Univ. Joensuu*
- [17] Abràmoff M D, Magalhães P J and Ram S J 2004 Image processing with ImageJ *Biophotonics Int.* **11** 36–42
- [18] Septadina I S, Murti K and Utari N 2018 Efek Pemberian Ekstrak Daun Kelor (*Moringa oleifera*) dalam Proses Menyusui. *SJM* **1** 74–9
- [19] Sambou Diatta B 2001 Supplementation for pregnant and breastfeeding women with *Moringa oleifera* powder *Development Potential for Moringa Products. International Workshop, Dar es Salaam, Tanzania.*
- [20] Prihati D R 2015 Pengaruh ekstrak daun kelor terhadap berat badan dan panjang badan anak tikus galur wistar *J. INFOKES APIKES CITRA.* **5** 15-22
- [21] Mishra S P, Singh P and Singh S 2012 Processing of *Moringa oleifera* leaves for human consumption *Bull. Environ. Pharmacol. life Sci.* **2** 28–31
- [22] Bhargave A, Pandey I, Nama K S and Pandey M 2015 *Moringa oleifera* Lam.—Sanjana (Horseradish Tree)—A miracle food plant with multipurpose uses in Rajasthan-India—an overview *Int J Pure App Biosci* **3** 237–48
- [23] Fahey J W 2005 *Moringa oleifera*: a review of the medical evidence for its nutritional, therapeutic, and prophylactic properties. Part 1 *Trees life J.* **1** 1–15
- [24] Rebecca H S U, Sharon M, Arbainsyah A and Lucienne D 2006 *Moringa oleifera*: medicinal and socio-economic uses *Int. Course Econ. Bot. Natl. Herb. Leiden, Netherlands* 2–6