

Multigravid Women with Uterine Rupture A Case Report

by Abarham Martadiansyah


Submission date: 10-May-2023 03:04PM (UTC+0700)

Submission ID: 2089317727

File name: Multigravid_Women_With_Uterine_Rupture_A_Case_Report.pdf (290.85K)

Word count: 2661

Character count: 14815



Bioscientia Medicina: Journal of Biomedicine & Translational Research

Journal Homepage: www.bioscimed.com

Multigravid Women with Uterine Rupture: A Case Report

Firmansyah Basir^{1*}, Adnan Abadi², Abarham Martadiansyah³, Cindy Kesty⁴, Febi Stevi Aryani⁴,
Murwani Emasrissa Latifah⁴

¹ Division of Social Obstetrics and Gynecology, Department of Obstetrics and Gynecology, Faculty of Medicine, Universitas Sriwijaya/ Mohammad Hoesin General Hospital, Palembang, Indonesia

² Division of Reproductive Endocrinology Infertility, Department of Obstetrics and Gynecology, Faculty of Medicine, Universitas Sriwijaya/ Mohammad Hoesin General Hospital, Palembang, Indonesia

³ Division of Maternal Fetal Medicine, Department of Obstetrics and Gynecology, Faculty of Medicine, Universitas Sriwijaya/ Mohammad Hoesin General Hospital, Palembang, Indonesia

⁴ Department of Obstetrics and Gynecology, Faculty of Medicine, Universitas Sriwijaya/ Mohammad Hoesin General Hospital, Palembang, Indonesia

ARTICLE INFO

Keywords:

Uterine rupture
Abdominal pain
Hysterorrhaphy
Pregnancy
Multigravide

*Corresponding author:

Firmansyah Basir

E-mail address:

firmaryahbasirspog@gmail.com

All authors have reviewed and approved the final version of the manuscript.

<https://doi.org/10.37275/bsm.v6i2.443>

ABSTRACT

Introduction: Uterine rupture is the discontinuation of the uterine scar that creates connection between uterine and peritoneal cavity. The most common etiology for uterine rupture is dehiscence of uterine scar tissue from previous cesarean section. In patient with uterine rupture and fetal expulsion to the peritoneal cavity, fetal survival becomes extremely poor. Therefore, it is important for clinician to understand the uterine rupture and be able to give prompt treatment in order to prevent maternal and fetal morbidity and mortality.

Case Presentation: A 34-year-old woman, G3P2A0 38 weeks of gestation complained that she had abdominal pain, couldn't feel her baby movement, watery discharge since 10 hours before admission. Bloody discharge and trauma were all denied. Patient underwent twice cesarean section before. Patient only had four times antenatal care with obstetrician at 24, 28, 32, and 36 weeks of gestation. She was scheduled for caesarean section at 38 weeks of gestation. Patient looked alert with low blood pressure and tachycardia. On physical examination, we found that she was pale, fundal height could not be determined, and there was no fetal heart rate detected. Speculum examination showed livide portio, closed external orifice of uterus, and inactive blood. There was positive slinger sign and Douglas cavity was bulging. Ultrasound examination showed intrauterine fetal demise, complete uterine rupture on lower segment, and positive sign of free fluid on abdominal cavity. Patient underwent operation and we found the died male neonate was in the peritoneal cavity and the placenta was still attached in the uterine cavity. We delivered the baby and placenta completely. There was uterine rupture on the previous CS scar, the edge of the uterine wound was regular with no necrosis and extended to the right side of uterus. Then, we performed hysterorrhaphy in order to stop the bleeding and repair the uterus, and we also performed tubal ligation. The died neonate had maceration grade I.

Conclusion: Uterine rupture causes poor fetal and maternal prognosis. Early diagnosis and prompt treatment is really important in uterine rupture. Prevention of uterine rupture could be done by meticulous antenatal care, especially visiting to obstetrician in order to review maternal and fetal condition and determine mode of delivery.

1. Introduction

Uterine rupture is the discontinuation of the uterine tissue creating connection between uterine and peritoneal cavity. A complete uterine rupture occurs when there is a direct connection between amnion and peritoneal cavity. This condition is extremely dangerous and mostly happens during labor and in patient with old pregnancy.¹ Uterine rupture occurs approximately 1:92 to 1:294 labor in big hospitals in

Indonesia. Study in Hasan Sadikin Hospital between 2000–2002 showed that there was a total of 168 cases of intrauterine fetal demise from 2,974 childbirths.² The most common etiology for intrauterine fetal demise is maternal factors, such as uterine rupture and diabetes mellitus. Mortality rate due to uterine rupture was reported at 50–75%.^{1,2}

The etiology of uterine rupture is multifactorial. The

most common cause is due to uterine scar dehiscence from previous cesarean section.^{2,3} Predisposition factors for uterine rupture include manipulation or traumatic operation like curettage, perforation, and myomectomy. Overstimulation of the uterus due to oxytocin can also cause uterine rupture, although it rarely happens these days.^{1,4} The prognosis of patient with uterine rupture is poor. In patient with uterine rupture and fetal expulsion to peritoneal cavity, the chance of fetal survival is extremely bad.⁵ Therefore, it is important for doctors to understand uterine rupture and be able to give prompt treatment in order to prevent maternal and fetal morbidity and mortality.

2. Case Presentation

G₃P₂A₀ 38 weeks of gestation complaining that she had abdominal pain, couldn't feel her baby movement, and water broke since 10 hours before admission. This was accompanied with sudden and severe abdominal pain. Bloody discharge and history of trauma were denied. Patient had history of 2 cesarean section in previous pregnancies. Patient only had four times antenatal care with obstetrician at 24, 28, 32, and 36 weeks of gestation. She was scheduled for caesarean section at 38 weeks of gestation. However, due to her complains, she went to emergency room at the nearest

regional hospital. Due to no on-duty-obstetrician, she was referred to another private hospital and scheduled for caesarean section 12 hours later. However, she and her family insisted to be referred to our hospital due to her unbearable complains.

Physical findings at our hospital showed that she seemed alert with low blood pressure at 100/70 mmHg, increased heart rate at 108 bpm, normal respiration rate at 22 times per minute, and normal body temperature at 36.8°C. On physical examination, we found her conjunctiva was anemic. Moreover, fundal height couldn't be determined and there was no fetal heart rate detected. Examination using speculum showed a livide portio with closed external orifice of uterus and inactive blood. From vaginal examination, the cervix was closed, there were positive slinger sign and bulged Douglas cavity.

In addition, laboratory findings showed mild anemia (hemoglobin 10.2 g/dL), increased leukocyte (12,830/mm³), normal platelet (388,000/μl), increased fibrinogen (486.0 mg/dL), increased D-dimer (7.12 mcg/mL), and increased hsCRP (26.0 mg/L). Besides that, urinalysis was positive for epithelia, bacteria and mucous. Ultrasound examination showed intrauterine fetal demise, complete uterine rupture on lower segment, and free fluid on abdominal cavity (Figure 1).

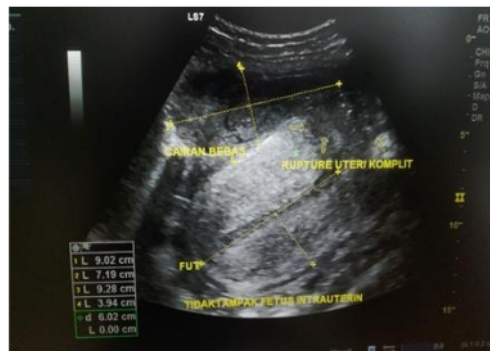

Figure 1. Ultrasound examination showed complete uterine rupture

Then, patient underwent operation. During operation, we found approximately 500 cc blood clot, the died male neonate was in the peritoneal cavity and the placenta was still attached in the uterine cavity. We delivered the baby with maceration grade I and placenta completely. There was uterine rupture on the previous CS scar. The edge of the uterine wound was

regular with no necrosis and extended to the right side of uterus. Then, we performed hysterorrhaphy in order to stop the bleeding and repair the uterus, and also tubal ligation. We also performed general condition improvement after several days. For example, PRC transfusion, albumin and calcium correction. Finally, she was discharged after 5 days.

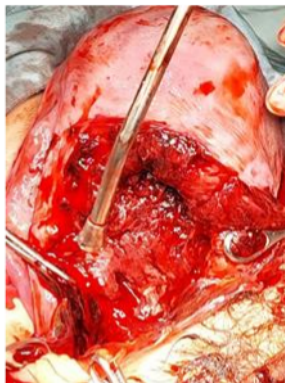

Figure 2. Intraoperative finding showed extended uterine wound

3. Discussion

Definition and etiology

Uterine rupture is tearing of the uterus that creates connection between uterine and peritoneal cavity. A complete uterine rupture occurs when there is a direct connection between amniotic cavity and peritoneal cavity. This is an extremely dangerous condition which mostly happens during labor and in woman with old pregnancy.¹ Uterine rupture can be caused by injury, existing anomaly, or complication during labor in uterus without scar tissue.^{1,2} Recently, the most common cause for uterine rupture is dehiscence of uterine scar tissue from previous cesarean section. This is probably due to increased trial of labor after cesarean delivery.²

Predisposition factors for uterine rupture includes history of manipulation or traumatic surgery, such as curettage, perforation, and myomectomy. Overstimulation of the uterus by oxytocin can also cause uterine rupture, although it rarely happens these days. In general, normal uterine without history of trauma that undergoes spontaneous delivery will not continuously contract until tearing occurs.^{2,3}

The risk factor for uterine rupture in this case was history of twice cesarean section. Rupture might be caused by uterine scar tissue dehiscence during contraction.

Diagnosis

The definite diagnosis of uterine rupture is established when clinicians identify a complete

disruption of all uterine layers on imaging or laparotomy. Uterine rupture must be suspected in patients presenting with (1) strong contraction, patient in severe pain, screaming as if her abdomen ruptured then become anxious, scared, pale, cold sweating, and collapse; (2) fast and shallow breathing; (3) vomiting due to peritoneal stimulation; (4) shock, fast and irregular heartbeat, dropping blood pressure; (5) vaginal bleeding, usually in small amount especially if the fetus head descends and obstructs the birth canal; (6) sometimes pain can radiate to lower extremities and shoulders; (7) loss of uterine contraction; (8) muscular defense occurs then abdomen become bloated and meteorism happened.^{2,4}

On palpation, we could find several findings, namely (1) crepitation due to subcutaneous emphysema on abdomen; (2) if fetus head has not descended, it is easier to release it from the pelvic inlet; (3) if fetus has been expelled from uterine cavity and in abdominal cavity, it can be directly palpated under abdominal skin with a hard uterus next to it; (4) tenderness on the ruptured part.²⁻⁴

On auscultation, we could find that fetal heart rate is not detected a few minutes following rupture, especially when placenta is expelled to abdominal cavity.²⁻⁴

On vaginal examination, we could find that fetus head can be easily released from pelvic inlet, causing a lot of blood from the vagina. If all uterine content has been expelled, clinician can feel rupture on the uterine wall and fetal part can be palpated.¹⁻³

In complete rupture, we could palpate as follow (1)

a smooth uterine surface and abdominal wall, (2) the edge of rupture, mostly occur on anterior lower uterine segment, (3) the intestine or omentum through the rupture, and (4) abdominal wall that can be pushed outward.^{1,2}

In this case, patient presented with sudden and severe abdominal pain, abdominal tenderness, muscular defense, fetal part can be palpated, and no fetal heart rate detected. These findings showed a possibility of massive hemorrhage in peritoneum that caused diaphragm irritation and pain. Patient looked alert with low blood pressure and tachycardia showing compensated shock. Laboratory investigation showed increased fibrinogen and D-dimer describing hypercoagulation condition. Increased hs-CRP indicated increased inflammation due to infection.

Management

Clinicians must carefully help delivery especially in labor with possible dystocia and woman with previous caesarean section or other surgery on the uterus to prevent uterine rupture. If the lower uterine segment stretches in dystocia, labor must be immediately completed.^{1,6} The survival of pregnant woman with uterine rupture depends on the swiftness and efficiency in managing hypovolemia and controlling bleeding. It should be noted that hypovolemic shock might not be able to improve before arterial bleeding is controlled, therefore delay in surgery can't be accepted.^{6,7} In patient with improved condition, we can perform total or subtotal hysterectomy, hysterorrhaphy, or conservative management with tamponade and antibiotic.⁷ The choice of management depends on patient's general condition, type of rupture (complete or incomplete), site of rupture, bleeding, age and number of healthy children, and doctor's capability.^{1,6}

Uterine rupture management consists of (1) infusing 500 ml isotonic fluid (ringer lactate or normal saline) in 10–20 minutes while preparing laparotomy; (2) performing laparotomy to evacuate the baby and placenta, primary health care facility must refer patient to hospital; (3) repairing the uterus if uterus conservation is needed and tissue is still viable; (4) in patient with extended necrosis and concerning condition, perform a hysterectomy; (5) giving wide

spectrum antibiotic if there is sign of infection and anti-tetanus serum (1500 IU/IM and TT 0.5 ml IM) if there is a sign of trauma on the genital or dirty wound.³

We managed the patient by observing vital signs and pain, oxygenation, fluid resuscitation, and explorative laparotomy. In this case, management was severely delayed (more than 10 hours since symptoms occurred) due to her financial issue. This led to intrauterine fetal restriction (2,300 grams) during pregnancy and eventually fetal demise. If not treated immediately, it could further cause uterine hypotonia or atony and maternal death due to hypovolemic shock.

Prevention

Uterine rupture can be prevented by careful evaluation especially during antenatal care. According to Royal College of Obstetrics and Gynaecologist, antenatal care in women with history of cesarean section should be done five times, namely at 12 weeks, 18–21 weeks, 21–28 weeks, 32–34 weeks and 36 weeks. More importantly, three visits to obstetrician are required with early visits (12 weeks of gestation) which is essential to determine mode of delivery.⁸ Careful review by history taking and lower uterine segment thickness would be done by obstetrician.⁹ However, in this cases, the patient only had two ANC with no review by obstetrician. Furthermore, due to twice cesarean sections that the patient had and no attempt or successful vaginal birth after cesarean (VBAC), the likelihood for morbidity and mortality is high if VBAC is planned.⁸

Useful mnemonic that explain cause of morbidity and mortality in expectant mother is "Tiga terlambat" or three delays (3D). Three delays consist of delayed diagnosis, delayed referral due to transportation and delayed management. In this particular case, it is delayed diagnosis by midwife, delayed referral due to late identification of condition and delayed management as when arrived, there has been fetal demise.¹⁰

4. Conclusion

Uterine rupture causes poor fetal and maternal prognosis. Doctors must have high suspicion for uterine rupture in pregnant woman presenting with

acute and severe abdominal pain. Early diagnosis and prompt treatment is really important in uterine rupture.

Prevention of uterine rupture could be done by meticulous antenatal care, especially visiting to obstetrician in order to review maternal and fetal condition and determine mode of delivery. Keep in mind "three delays" that is the cause of maternal mortality which is delayed in diagnosing, referral, and management. In this particular case, there are delayed referral due to late diagnosis and delayed management as when arrived at our hospital, there has been fetal demise.

5. References

1. Cunningham F, Gant N, Leveno K, Gilstrap III L, Hauth J, Wenstrom K. Deep obstetric hemorrhage. In: Profitasari, Hartantao H, Suyono Y, Yusna D, Kosasih A, Prawira J, et al., editors. Williams Obstetrics. 1st ed. Jakarta: EGC; 2006; 716–23.
2. Fedorkow D, Nimrod C, Taylor P. Ruptured uterus in pregnancy: A Canadian hospital's experience. *CMAJ*. 2008; 137:27
3. Martohoesodo S, Marsianto. Injuries and other events in labour. In: Saifuddin A, Rachimhadhi T, Winkjosastro G, editors. Midwifery Science. 4th ed. Jakarta: Sarwono Prawirohardjo Bina Pustaka Foundation; 2008; 668–72.
4. ACOG. Practice bulletin no. 205: Vaginal birth after cesarean delivery. *Obs Gynecol*. 2019; 133(2): e110–27.
5. Nagaya K, Fetters M, Ishikawa M, Kubo T, Konayagi T, Saito Y, et al. Causes of maternal mortality in Japan. *JAMA*. 2000; 283:2661
6. . 6. Togioka B, Tonismae T. Uterine rupture. *StatPearls*. 2020.
7. Rottenstreich M, Rotem R, Hirsch A, Farkash R, Rottenstreich A, Samueloff A, et al. Delayed diagnosis of intrapartum uterine rupture - maternal and neonatal consequences. *J Matern Fetal Neonatal Med*. 2021; 34(5): 708–13.
8. RCOG. Birth after previous caesarean birth. RCOG Green-top guidelines. 2015; 1–31.
9. Jastrow N, Demers S, Chaillet N, Girard M, Gauthier RJ, Pasquier JC, et al. Lower uterine segment thickness to prevent uterine rupture and adverse perinatal outcomes: A multicenter prospective study. *Am J Obs Gynecol*. 2016; 215(5): 604–6.
10. Hespati SH, Sulistiyowati S, Nababan R. Analysis of determinants of maternal mortality in Sukoharjo Regency, Central Java, Indonesia. *J Reproductive Health*. 2019; 6(2): 52–9.

Multigravid Women with Uterine Rupture A Case Report

ORIGINALITY REPORT

9%

SIMILARITY INDEX

7%

INTERNET SOURCES

7%

PUBLICATIONS

4%

STUDENT PAPERS

PRIMARY SOURCES

1	"Abstract", Journal of Obstetrics and Gynaecology Research, 2023 Publication	2%
2	Yunni Diansari, Selly Marisdina, Afriani, Dya Anggraeni, Hediaty Syafiera. "The Concordance of Recursive Partitioning Analysis (RPA) Class Stratification with Survival of Brain Metastases Patients in Mohammad Hoesin Hospital, Palembang, Indonesia", Bioscientia Medicina : Journal of Biomedicine and Translational Research, 2020 Publication	1%
3	eurekabiomedical.com Internet Source	1%
4	actamedindones.org Internet Source	1%
5	www.thieme-connect.com Internet Source	1%
6	iksadyayinevi.com Internet Source	1%

-
- 7 Submitted to University of Central Oklahoma <1 %
Student Paper
-
- 8 ijsra.net <1 %
Internet Source
-
- 9 lisyam90.wordpress.com <1 %
Internet Source
-
- 10 www.spandidos-publications.com <1 %
Internet Source
-
- 11 Francesco Cavallieri, Alessandro Marti, Antonio Fasano, Annalisa Dalla Salda et al. <1 %
"Prothrombotic state induced by COVID-19 infection as trigger for stroke in young patients: A dangerous association.", eNeurologicalSci, 2020
Publication
-
- 12 Lindsey A. Choi, Ariel A. Chung, Brian Pierce. <1 %
"Late Presentation of Uterine Rupture Following Vaginal Birth After Cesarean Delivery: A Case Report", American Journal of Perinatology Reports, 2020
Publication
-

Exclude quotes On

Exclude matches < 2 words

Exclude bibliography On

Multigravid Women with Uterine Rupture A Case Report

GRADEMARK REPORT

FINAL GRADE

/0

GENERAL COMMENTS

Instructor

PAGE 1

PAGE 2

PAGE 3

PAGE 4

PAGE 5
