

PERBANDINGAN EKSPRESI PROTEIN p53 MUTAN PADA KELOMPOK PTERYGIUM DENGAN DAN TANPA INJEKSI TRIAMCINOLONE ACETONATED

by Riani Erna

Submission date: 14-Jun-2023 03:26PM (UTC+0700)

Submission ID: 2115826749

File name: ifransiska,_2._dr.riani.pdf (391.96K)

Word count: 3393

Character count: 18919

PERBANDINGAN EKSPRESI PROTEIN *p53* MUTAN PADA KELOMPOK PTERYGIUM DENGAN DAN TANPA INJEKSI TRIAMCINOLONE ACETONITED

Riani Erna,¹ Eva Kumalasari,² Ika Kartika Edi³

¹Bagian Kesehatan Mata Fakultas Kedokteran Universitas Sriwijaya

²PPDS 1 Kesehatan Mata Fakultas kedokteran Universitas Sriwijaya

³Bagian Patologi Anatomi Fakultas Kedokteran Universitas Sriwijaya

COMPARISON OF MUTANT *P53* PROTEIN EXPRESSION IN PTERYGIUM GROUP WITH AND WITHOUT TRIAMCINOLONE ACETONITED INJECTION

ABSTRACT

Background: Mutant *p53* protein is produced by mutant *p53* gene, this protein takes part in tissue hyperplasia process in pterygium. Triamcinolone acetonide is often used to reduce recurrence. Besides decreasing the inflammation triamcinolone acetonide is assumed to be able to repair the function of *p53* gene. Thus, it reactivates cell apoptosis system and prevent the tissue hyperplasia process in pterygium. To compare Mutant *p53* Protein Expression in Pterygium Group With and Without Triamcinolone Acetonide Injection

Methods: This research is a randomized clinical trial study consists of 31 subject who suffered primary pterygium. All subject divided into 2 grup with and without triamcinolone acetonide injection. After excision the pterygium and the tissue were examined through histopatology and immunohistochemical with Hematoxyline Eosin and reagent Clone DO7 staining to see the mutant *p53* protein expression.

Results: Mutant *p53* protein expression in triamcinolone acetonide injected group is 0% and non triamcinolone acetonide injected group is 33,33%

Conclusion: Mutant *p53* protein expression in triamcinolone acetonide injected group is lower than non injected group.

Keywords: Mutant *p53* protein, primary pterygium, triamcinolone acetonide immunohistochemical

ABSTRACT

Latar Belakang: Protein *p53* mutan merupakan protein yang dihasilkan oleh gen *p53* yang mengalami mutasi, protein ini berperan pada proses hiperplasia jaringan pada pterygium. Triamsinolon asetat sering digunakan untuk mengurangi rekurensi. Selain untuk mengurangi inflamasi triamsinolon asetat diduga dapat memperbaiki fungsi gen *p53* sehingga mengaktifkan kembali sistem apoptosis sel dan mencegah proses hiperplasia jaringan pada pterygium.

Tujuan: Untuk membandingkan ekspresi reseptor Protein *p53* mutan antara kelompok penderita pterygium yang diinjeksi triamsinolon asetat dan kelompok penderita pterygium tanpa injeksi triamsinolon asetat.

Metode: Penelitian ini merupakan penelitian uji klinis acak yang terdiri dari 31 orang penderita pterygium primer. Seluruh subjek penelitian kemudian dibagi kedalam 2 kelompok, yang diinjeksi triamsinolon asetat dan tanpa injeksi triamsinolon asetat. Setelah di eksisi pterygium dipulas dengan pewarnaan HE dan reagent Clone DO7 untuk menilai ekspresi protein *p53* mutan.

Hasil: Ekspresi protein *p53* mutan pada kelompok penderita pterygium yang diinjeksi triamsinolon asetat 0% dan pada kelompok penderita pterygium tanpa injeksi triamsinolon asetat sebesar 33,33%.

Kesimpulan: Ekspresi protein *p53* mutan pada kelompok penderita pterygium yang diinjeksi triamsinolon asetat lebih rendah dibandingkan dengan kelompok penderita tanpa injeksi triamsinolon asetat.

Kata Kunci: Protein *p53* mutan, pterygium, triamsinolon asetat, imunohistokimia.

¹ Alamat Koresponding: Riani Erna, Staf Pengajar Bagian Kesehatan Mata Fakultas Kedokteran Universitas Sriwijaya, Jl. Jendral Sudirman Komp RSUP Dr. Moh Hoesin Palembang 30126 email: rianierna@gmail.com

INTRODUCTION

Pterygium is a degeneration and hyperplasia process of fibrous tissue in the form of a triangle in the conjunctiva along the interpalpebral fissure with a centralized peak or in corneal region.¹⁻⁸ Pterygium prevalence varies by race, age, gender, and geographic location. In Indonesia, the prevalence of pterygium in patients over 40 years old is 10%. Men has higher risk than women. In general, the prevalence of pterygium in the tropics is higher than in sub-tropics region. This occurs because exposure to ultraviolet (UV) rays in the tropics is higher than subtropical regions.¹⁻¹²

UV exposure can also cause damage to DNA causing inactivation of the p53 gene which is one of the gene suppressor tumors that play a role in controlling cell cycle, cell differentiation, and apoptosis.¹⁻¹⁷ This is supported by several studies showing the abnormal expression of the mutant p53 protein in more than 50% of patients with pterygium.¹⁸⁻²⁴ Management of pterygium is conservative and operative generally. Because of the high recurrence rate after excision as many as 24% to 89%, the operative is only performed on cases that cause visual disturbance, irritation that can not be reduced with medicamentosa, detention of eyeball movement due to pterygium growth.^{1,4-7}

Triamcinolone acetate, which is a synthetic corticosteroid, is thought to decrease pterygium recurrence. Triamcinolone acetate acts as an anti-inflammatory by inhibiting fibroblast forming activity, slowing epithelial and endothelial regeneration processes and reducing neovascularization after inflammation.^{13,14}

In cases of leukemia, lymphoma and myeloma, glucocorticoids used as chemotherapy to increase apoptosis in blood cells. Crochemore et al. conducted a study of nerve cells and found that steroid may activate glucocorticoid receptors that would increase p53 activity resulting inhibit in neural cell

proliferation.²⁵⁻²⁷ Similarly, in pterygium, it is expected that corticosteroid, such as triamcinolone acetate before pterygium surgery can act as a therapeutic adjuvant to increase the level of wild-type p53 or decrease the expression of p53 mutant type protein, and there after may reduce pterygium recurrence after anti-metabolite or radiation therapy.

In Indonesia, especially in Palembang, study in evaluating of mutant p53 protein expression in pterygium patient which got triamnisolone acetate had been don yet.

The aim of this study was to find out whether the expression of p53 mutants protein in the pterygium group injected triamcinolone acetate was lower than the expression of p53 mutant protein in the pterygium group without triamcinolone acetate injection.

MATERIAL AND METHODS

This study is randomized clinical trials study by single blinded form conducted in Reconstruction Subdivision Ophthalmology Departement FK Unsri / RSMH Palembang, satelit hospital, and Pathology Anatomy Laboratory RSMH Palembang. This study conducted in April 2013 to August 2013 (until the number of samples was fullfill). The population was all primary pterygium patients who underwent primary pterygium excision with or without conjunctival graft which fulfilled inclusion and exclusion criteria and were willing to participate in this study. Samples were taken by consecutive sampling technique.

The inclusion criteria are all primary pterygium grade II patient or more who will undergo pterygium excision surgery at RSMH / Ophthalmology Departement satelit hospital. Exclusion criterion is pseudopterygium, history of topical steroid use at last 2 weeks ago. Drop out criteria if in sampling specimen is not sufficient for histopathological examination and patient is out of control 1 week after injection of triamcinolone acetate.

Procedure of Study

Patients with pterygium, who will undergo excision surgery, who fulfill sample criteria and willing to take part in the study, are divided into two groups by simple randomization. In the first group, a 0.2 ml triamcinolone acetate was administered in subconjunctiva 1 week before excision. After one week post-injection, excision of pterygium was performed. While in the second group, triamethinolone acetate injection was not performed prior to excision. Excision is performed in the operating room. After excision, the pterygium tissue previously marked on the superior and inferior parts of the limbus is inserted into a container containing 10% formaldehyde buffer solution, and sent to Pathology Anatomy laboratory for immunohistochemical assessment. Histopathologic and immunohistochemical assessments were performed by an Pathology Anatomy physician who did not know which group of treated sample.

Triamcinolone acetate injection procedure

1. The patient lies supine in an aseptic antiseptic condition.
2. The operator uses sterile gloves
3. 2% tetracaine imprinted on the conjunctiva
4. Blepharostat installed
5. Conjunctiva removed by using sterile conjunctival tweezers
6. 0.2 ml triamcinolone acetate was injected in subconjunctiva
7. chloramphenicol eye ointment is administered in conjunctiva and then conjunctiva is covered with sterile gauze.

Procedure of excision of pterygium with or without conjunctival graft.

1. The patient lies supine in an aseptic antiseptic condition.
2. The operator uses sterile gloves

3. topical anesthetic is administered
4. Blepharostat is installed
5. Lidocaine HCl 2% is administered in subkonjungtiva on pterigium tissue till the head of pterygium in cornea. The base of the pterygium tissue is separated from sclera, separating the attachment in the limbus is done bluntly and sharply by using the Wescott scissors. The attachment of the pterygium in the cornea is released by peeling off the tissue toward the center of the cornea gently. Clean the limbus area and the pterygium residue in the cornea bluntly. The pterygium tissues in the superior and inferior limbus regions are marked with yarn. Bleeding is treated with a bandage or diathermy.

The procedure for pterygium excision with conjunctival autograft is done by interuptus stitching conjunctival graft in pterigium region with vicryl 8.0. Stitching must accompany suture sclera and attempted to bring together the edge of the incision conjunctiva as far as possible. eyes are given anti-biotic ointment and closed until the next day and the patient was given analgesics and a drops of steroid four times daily.

RESEARCH RESULT

The study involved 31 subjects consisting of 16 subjects with subconjunctiva triamcinolone acetate injection and 15 subjects without triamcinolone acetate injection. Characteristics of research subjects are shown in Table 1.

Gender

In this study, in the TA injection group, there were as many patients as male and female, 8 people, whereas in the group without TA injection there were 5 patients with male sex and 10 female patients. Statistical analysis showed that there were no

gender differences between patients with and without TA injection

Table 1.
Sample Distribution Based On Gender

| Characteristic Demography | With TA Injection | Without TA Injection | p value |
|---------------------------|-------------------|----------------------|---------|
| Gender | | | |
| Male | 8 (50.0) | 5 (33.3) | 0.565 |
| Female | 8 (50.0) | 10 (66.7) | |
| Total | 16 | 15 | |

Age

The majority of groups with TA injection were aged 40-49 years while in the group without TA injection aged 50-59 years. With statistical analysis, there is no difference in age categories between patients with and without TA injection

Table 2.
Sample Distribution Based On Age

| Characteristic Demography | With TA Injection | Without TA Injection | p value |
|---------------------------|-------------------|----------------------|--------------------|
| Age (year) | | | |
| 20-29 | 1 (6.3) | 0 (0) | 0.071 ^b |
| 30-39 | 4 (25.0) | 2 (13.3) | |
| 40-49 | 8 (50.0) | 3 (20.0) | |
| 50-59 | 1 (6.3) | 7 (46.7) | |
| ≥ 60 | 2 (12.5) | 3 (20.0) | |
| Total | 16 | 15 | |

Uji Chi Square

Occupation

In this study patients working outdoors consisted of drivers, motorbike drivers,

rickshaw pullers, farmers and charcoal makers while patients working indoors consisted of housewives, teachers/lecturers and civil servants. In the group with TA injection there were 11 people who worked outdoors while in the group without injection there were 7 people who worked outdoors. Statistical analysis showed that there were no occupation differences between patients with and without TA injection.

In addition, the expression of p53 mutants in patients who worked outdoors was lower than indoors but the difference was not statistically significant.

Table 3.
Expression of p53 Mutants in Pterygium Patients Indoor and Outdoor Occupation

| Variabel | Occupation | | p value |
|-------------------|------------|-------------|---------|
| | Outdoor | Indoor | |
| p53 Mutan | | | |
| -Mean ± SD | 2,89 ± 2,8 | 10,0 ± 14,4 | 0,099 |
| -Median (Min-Max) | 1 (0-10) | 5 (0-50) | |

History of Family

All patients in the TA injection group did not have a family history whereas in the no-injection group 5 out of 15 patients had a family history. Statistical analysis showed that there were difference in history of family between patients with and without TA injection.

Table 4.
Sample Distribution Based On History of Family

| Characteristic Clinic | With TA Injection | Without TA Injection | p value |
|-----------------------|-------------------|----------------------|---------|
| History of Family | | | |
| Present | 0 | 5 | 0,018 |
| Absence | 16 | 10 | |
| Total | 16 | 15 | |

Uji Fisher Exact

In this study, the expression of p53 mutants in patients who had a family history was higher than those compared

to patients without family history and the difference was statistically significant

Table 5.
Expression of p53 Mutants in Pterygium Patients With and Without Family History

| Variabel | History of Family | | p value |
|-------------------|-------------------|------------|---------|
| | Present | Absence | |
| p53 Mutan | | | |
| -Mean ± SD | 22,0 ± 17,9 | 2,77 ± 2,6 | 0,129 |
| -Median (Min-Max) | 10 (10-50) | 1 (0-10) | |

Pterygium Duration

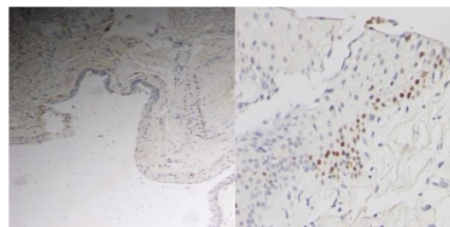
The majority of groups with TA injection have duration of pterygium 5-6 years while in the group without injection TA suffered 4-5 years and 7-8 years. With

statistical analysis, there was no difference in the pterygium duration between patients with and without TA injection.

Table 6.
Sample Distribution Based On Duration Pterygium

| Characteristic Clinic | With TA Injection | Without TA Injection | p value |
|-----------------------|-------------------|----------------------|---------|
| Duration Pterygium | | | |
| 1-2 | 2 (12.5) | 0 (0) | 0,063 |
| 3-4 | 5 (31.3) | 5 (33.3) | |
| 5-6 | 8 (50.0) | 3 (20.0) | |
| 7-8 | 1 (6.2) | 5 (33.3) | |
| 9-10 | 0 (0) | 0 (0) | |
| 11-12 | 0 (0) | 2 (13.4) | |
| Total | 16 | 15 | |

Uji Chi Square



a.Magnification 100x

b.Magnification 400x

Figure 1.
Staining of Mutant p53 at Pterygium Epithelial Nucleus Cell

DISCUSSION

Triamcinolone acetate is a synthetic glucocorticoid that has anti-inflammatory effects. It has a moderate life time (12-36 hours) and does not cause sodium retention. Corticosteroids as anti-inflammatory have been known reduce the recurrence of pterygium. In some studies, the rate of pterygium recurrence of patients who receive adequate topical corticosteroid therapy was lower than in patients receiving inadequate topical corticosteroid therapy after pterygium surgery. Yaisawang et al got from 142 eyes pterygium who undergo surgery, there was 21 patients who experienced recurrence, 5 people of them received adequate topical corticosteroid therapy while 16 people of them with inadequate topical corticosteroid therapy after surgery. A 0.2 ml subconjunctiva of triamcinolone acetate may be injected to recurrence pterygium after surgery and may be repeated 3 times of 2 weeks interval.^{13,14}

Handoko et al conducted a study which obtained 64 primary progressive pterygium, where there was a difference in the number of stained cells between the pterygium patient with triamcinolone acetate injection and pterygium patient without triamcinolone acetate injection.⁴⁶ Study conducted by P Anguria et al in Lampopo concluded that people who have a family history suffered from pterygium had a risk of suffering from pterygium 3.93 times greater than those without a family history of suffering from pterygium. Whereas in a study conducted by Booth in Australia, there are 38% of patients with pterygium performed excision surgery had a family history of pterygium.⁴⁷⁻⁴⁹

In some studies, stated mutant p53 protein expression with cut off > 10% was associated with p53 gene mutation whereas mutant p53 protein expression with cut off <10% was associated with cell proliferation activity.²¹ To find out the influenced of gender in p53 expression in this study, Spearman's correlate analysis was done,

which there was no relationship between gender with the number of stained cells ($\rho = 0.198$, $p = 0.286$). Ueda et al reported in men has higher stained cells than women because the occupation of men mostly outdoors so more exposed to the sun. While in study conducted by Tsai in Taiwan, gender had no influence on p53 expression.

Study conducted by Hiroki et al reported different things where the prevalence of pterygium in men is greater than in women. In contrast, Gazzard et al and Durkin SR et al reported the same thing in which there was no significant difference in gender distribution of pterygium.⁴²⁻⁴⁴ Farmers or workers in the plantation is the most occupation in this study as many as 13 subjects (40.62%). These is according to study which conducted by Gazzard et al, Durkin SR and Hiroki et al They are explaining that outdoor work has higher risk to pterygium events. Meanwhile, according to Rajiv Luthra et al people who work outdoors have a risk 1.87 times to suffer from pterygium compared to people working indoors.

This study evaluate this time it is only used after (injection of subconjunctival triamcinolone acetate one week before surgery) compared to the non-specific and cannot be found the amount of mutant p53 protein in pterygium tissue that has received triamcinolone acetate injection is indeed related to before receiving triamcinolone acetate injection. In this study there were also no measurements that occurred after performing surgery in both treatment groups.

CONCLUSION

Expression of protein p53 mutant in group of pterygium patient who received injection of triamcinolone acetate 0% and in group of pterygium patients who did not get injection of triamcinolone acetate for 5 (33,33%) Expression of protein p53 mutant in group of pterygium patients injection of triamcinolone acetate was lower than pterygium group without injection of

triamcinolone acetate ($p = 0.018$, two tail). Further requirements with larger and longer samples can be used to determine whether there is a better and better risk than those that can be used for surgery. Make

histopathological examination and Imuno Histo Chemical Examination as a postoperative operational standard to monitor and prevent recurrence hazards.

REFERENCES

1. Sao Bing Lee. Pterygium: an update concept and treatment modality. *Ophthalmology Rounds*: 2004;2,(7).
2. Chui J, Coroneo Minas. Ophthalmic pterygium: a stem cell disorder with premalignant features. *The American Journal of Pathology*. 2011;178(2):817-827
3. M T Coroneo. Pterygium as an early indicator of ultraviolet insolation: a hypothesis. *British Journal of Ophthalmology*. 1993;77:734-739
4. Detorakis E, Spandidos. Pathogenic mechanism and treatment option for ophthalmic pterygium: trends and perspective. *International Journal of Molecular Medicine* . 2009;23:439-447
5. Hovanesian J. Pterygium techniques and technologies for surgical succes. *Slack Incorporated*:2012.
6. Skuta GL, Cantor B, Weiss JS, et al. Surgery of the ocular surface. In: *External eye disease*. San Fransisco. 2012;sec 8;chapter 14; 391-3.
7. Skolnick C. Management of pterygium. *Sec 2. Conjunctival surgery*, p.1745-1761.
8. Tradjutrino. Pterygium: degeneration, exuberant wound healing or benign neoplasm?. *Universa Medicina*;2009;28(3):179-187.
9. Daya Papalkar. Inflammation associated S100 protein in pterygium, tears, and uv irradiated murine corneas. *Faculty of Medicine*. University of New South Wales. 2010.
10. Zaki A , Emerah S , Ramzy M. Management of recurrent pterygia. *Journal of American Science*. 2011;7(1),230-4
11. Dzunic B, Jovanovic P. Comparative analysis of pterygium clinical characteristic. *ACTA FAC MED NAISS*. 2009; 26 (2): 77-83
12. Kun L, Zhengxuan J. Expression of cell proliferation and apoptosis biomarkers in pterygia and normal conjunctiva. *Molecular Vision*. 2011;17:1687-1693 <<http://www.molvis.org/molvis/v17/a187>>
13. Paris et all. Postoperative subconjunctival corticosteroid injection to prevent pterygium recurrence. *Cornea*:2008;27(4):406-410.
14. Yaisawang S. Role of post operative topical korticosteroids in recurrence rate after pterygium excision with conjunctival autograft. *J. Med ASSOC Thai*. 2003;86 Suppl 2:S215-23.
15. Syaifudin M. Gen penekan tumor p53, kanker dan radiasi pengion. *Pusat Teknologi Keselamatan dan Metrologi Radiasi – BATAN*. *Buletin Alara*. 2007;8(3):119–128.
16. Hamdani C, Siregar NC. Terapan onkologi. Dalam: *Patologi olekular*. Jakarta. 2012:Badan Penerbit FKUI: Bab 4;115-135.
17. Syaifudin M. Gen penekan tumor p53 sebagai pelindung sel dari radiasi pengion. *Prosiding Presentasi Ilmiah Keselamatan Radiasi dan Lingkungan*. Desember . 2004.
18. membrane grafts. *Pak J Ophthalmol*. 2010;26;(3):138-142
19. Underwood. *Patologi umum dan sistematik*. Editor bahasa Indonesia: Sarjadi. Ed 2;EGC;1999;290-4
20. Gen p53, tersedia pada http://p53.free.fr/p53_info/p53_gene.htm
21. Rivlin N, Brosh R, Oren M. Mutations in the p53 Tumor Suppressor Gene: Important milestones at the various steps of tumorigenesis. *Genes & Cancer* 2011;2: 466
22. Tsai YY, Chiang CC et all. Pterygium and genetic polymorphisms of the DNA repair enzymes XRCC1, XPA and XPD. *Molecular Vision* 2010;16:698-704

23. Young CH, Lo YL, Tsai YY et al. CYP1A1 gene polymorphisms as a risk factor for pterygium. *Molecular vision* 2010;16:1054-58
24. Handoko SB. Perbandingan ekspresi p53 pada pterigium primer progresif dengan dan tanpa injeksi triamcinolone acetone. 2008
25. Peter Anguria, Sam Ntuli. Relationship of heredity and dry eye with pterigia in black African patient. *SAMJ*. 2011;101:2
26. P. Anguira. Traditional eye medication and pterygium occurrence in Limpopo Province. *S.Afr. Med J*. 2012;102(8):687-690.
27. Booth F. Heredity in one hundred patient admitted for excision of pterygia. *Aust NZ J Ophthalmol*.1985;13:59-61.

PERBANDINGAN EKSPRESI PROTEIN p53 MUTAN PADA KELOMPOK PTERYGIUM DENGAN DAN TANPA INJEKSI TRIAMCINOLONE ACETONITED

ORIGINALITY REPORT

5%

SIMILARITY INDEX

4%

INTERNET SOURCES

3%

PUBLICATIONS

3%

STUDENT PAPERS

PRIMARY SOURCES

1

Submitted to Sriwijaya University

Student Paper

3%

2

Riza Aswarin, Muhtarum Yusuf, M. S. Wiyadi.

"Association of Protein Expression p53

Mutants with Regional Lymph Gland Status on

type III Carcinoma Nasofaring Patients",

Indian Journal of Otolaryngology and Head &

Neck Surgery, 2018

Publication

1%

3

perpustakaan.fk.ui.ac.id

Internet Source

1%

Exclude quotes On

Exclude matches < 1%

Exclude bibliography On