

BUKTI KORESPONDENSI ARTIKEL JURNAL NASIONAL TERAKREDITASI

Judul Artikel : Correlation of Microvessel Density with Clinicopathological Features of Hodgkin Lymphoma

Nama Jurnal : Indonesian Journal of Pathology

Penulis : M.Bima Zulfikar, Krisna Murti*, Iche Andriyani Liberty, Citra Dewi, Riana Sari Puspita Rasyid

No	Perihal	Tanggal
1	Bukti Konfirmasi Submit Artikel	28 Januari 2022
2	Bukti Konfirmasi Review	15 Februari 2022
3	Bukti Submit Hasil Revisi	7 Maret 2022
4	Bukti Permintaan Perubahan Bahasa Pada Artikel	30 November 2022
5	Bukti Submit Perubahan Bahasa	3 Januari 2023

Bukti Konfirmasi Submit Artikel (28 Januari 2022)



Krisna Murti unsri <krisna.arinafril@unsri.ac.id>

Submit artikel ke-2 th 2022 by dr. Krisna Murti

Krisna Murti unsri <krisna.arinafril@unsri.ac.id>
To: mpi iapi <mpi.iapi@gmail.com>

Fri, Jan 28, 2022 at 8:58 AM


Kepada Yth.
Bapak Rubikin
Sekretariat Redaksi MPI IAPI
Jakarta

Dengan hormat,

Berikut ini kami kirimkan artikel ke-2 kami yang berjudul "Kepadatan Microvessel di Lingkungan Mikro Tumor Limfoma Hodgkin". Mohon agar artikel kami dapat diterima untuk di terbitkan di Majalah Patologi Indonesia. Kami mohon di infokan jika ada koreksi dan akan secepatnya kami perbaiki.

Atas perhatian dan bantuan, kami ucapkan terima kasih.

dr. Krisna Murti, M.Biotech., Stud., PhD., SpPA(K).
Departemen Patologi Anatomi FK Unsri
Palembang.

 **Manuskrip M. Bima Zufikar-KM-28.01.22.docx**
1095K

Bukti Konfirmasi Review (15 Februari 2022)



Krisna Murti unsri <krisna.arinafril@unsri.ac.id>

Mohon Revisi Artikel

mpi iapi <mpi.iapi@gmail.com>

Tue, Feb 15, 2022 at 11:02 AM


To: Krisna Murti unsri <krisna.arinafril@unsri.ac.id>

Kepada Yth.
dr. Krisna Murti, M.Biotech.Stud., PhD., SpPA(K).
Dep. Patologi Anatomi FK Unsri
Palembang.

Dengan hormat,
Berikut ini kami kirimkan hasil review artikel "Kepadatan Microvessel pada Lingkungan Mikro Tumor Limfoma Hodgkin".
Mohon kiranya dapat dilakukan perbaikan sesuai dengan arahan dan permintaan Redaksi Ahli.
Perbaikan/Revisi agar dilakukan pada soft copy artikel yang kami kirim untuk mempermudah proses editing selanjutnya.

2 attachments

 **03FormReview-KepadatanMicrovesselPadaLingkunganMikroTumorLimfomaHodgkin-Ke Penulis-
M.BimaZulfikar.pdf**
204K

 **03M.BimaZulfikar-KepadatanMicrovesselPadaLingkunganMikroTumorLimfomaHodgkin-Terima31Jan'22-
Edit.docx**
845K



FORMAT PENILAIAN NASKAH MPI HASIL PENELITIAN

(Untuk Penyunting Ahli)

Judul Naskah : **Kepadatan Microvessel pada Lingkungan Mikro Tumor Limfoma Hodgkin**
 Tanggal Kirim : Tanggal Kembali Ke Redaksi : **10/2/22**

Komentar/Perbaikan : (Dapat ditulis tangan/diketik, gunakan lembar tambahan bila diperlukan).

1. Judul. *Judul tak sesuai dg isi.*
 Usul: *ganti judul sesuai isi: Hubungan MVD dengan sbran HPATH pd LH.*
2. Abstrak
cukup
3. Pendahuluan.
cukup
4. Metode Penelitian. *cukup.*
 Usul: *Masukkan variable stadium.*
5. Hasil. *Mungkin bila stadium dimskan sbg variabel sbran HP hasil lebih baik.*
Sebab angiogenesis → prognosis → stadT → angiogenesis > k
6. Diskusi.
Coba artikel direvisi mudah au berhasil baik
7. Kesimpulan.
Coba direvisi smg kesimpulan lbh baik.
8. Daftar Pustaka.
cukup
9. Cara Penulisan.
cukup
10. *Pertanyaan: - kap pemb darah yg bgms yg dihitung, bentuk strukturnya? Bukankah yg dihitung str pd yg baik strukturnya.?*

Koreksi dapat dilakukan langsung pada naskah.

FORMAT REKOMENDASI untuk REDAKSI/ Penyunting Pelaksana.

- () 1. Naskah dapat dimuat tanpa perubahan.
- () 2. Naskah dapat dimuat dengan perbaikan sesuai dengan arahan.
- (.....) 3. Naskah dapat dimuat dengan perbaikan format dan bahasa.
- (.....) 4. Naskah tidak dapat dimuat.

Redaksi Ahli MPI,

Bukti Submit Hasil Revisi (7 Maret 2022)



Krisna Murti unsri <krisna.arinafril@unsri.ac.id>

Submit Revisi manuskrip Bima Zulfikar (dr. Krisna Murti, SpPA(K), Ph.D)

Krisna Murti unsri <krisna.arinafril@unsri.ac.id>
To: mpi iapi <mpi.iapi@gmail.com>

Mon, Mar 7, 2022 at 10:06 PM

Kepada Yth.
Bapak Rubikin
Sekretariat Redaksi MPI IAPI
Jakarta

Dengan hormat,

Berikut ini kami kirimkan hasil Revisi artikel kami yang berjudul "**Hubungan Kepadatan *Microvessel* dengan Gambaran Histopatologi pada Limfoma Hodgkin**". Mohon agar artikel kami dapat diterima untuk di terbitkan di Majalah Patologi Indonesia. Kami mohon di infokan jika ada koreksi lagi dan akan secepatnya kami perbaiki.

Atas perhatian dan bantuan, kami ucapkan terima kasih.

dr. Krisna Murti, M.Biotech., Stud., PhD., SpPA(K).
Departemen Patologi Anatomi FK Unsri
Palembang.

 **REVISI Manuskrip Bima Z-by KM 07.03.2022.docx**
840K

**Bukti Permintaan Perubahan
Bahasa pada Artikel (30
November 2022)**



Krisna Murti unsri <krisna.arinafril@unsri.ac.id>

Perubahan Penggunaan Bahasa pada Artikel MPI

mpi iapi <mpi.iapi@gmail.com>

Wed, Nov 30, 2022 at 12:28 PM

To: Krisna Murti unsri <krisna.arinafril@unsri.ac.id>

Kepada Yth.

dr. Krisna Murti, M. Biotech. Stud., Ph.D., SpPA(K)

Departemen Patologi FK Universitas Sriwijaya

Palembang

Dengan hormat,

Dalam rangka meningkatkan kualitas penerbitan MPI dan persiapan akreditasi pada tahun 2024, dengan ini diberitahukan bahwa terhitung mulai penerbitan tahun 2023 semua artikel yang akan dimuat diharuskan memakai bahasa Inggris.

Sehubungan dengan hal tersebut, mohon kiranya Saudara dapat mengalihbahasakan artikel yang sudah siap untuk di-*lay out* menjadi bahasa Inggris seluruhnya. Untuk perubahannya bisa langsung pada file word yang kami kirimkan.

Atas perhatiannya kami ucapkan terima kasih

Sekretariat MPI

2 attachments



096Surat Pemberitahuan Perubahan Bahasa Artikel.pdf

107K



03M.BimaZulfikar-KepadatanMicrovesselPadaLingkunganMikroTumorLimfomaHodgkin-Terima31Jan'22-SiapLayOut.docx

433K



PERHIMPUNAN DOKTER SPESIALIS PATOLOGI INDONESIA
Indonesian Association of Pathologists

I A P I
MAJALAH PATOLOGI INDONESIA

Departemen Patologi Anatomi, Fakultas Kedokteran Universitas Indonesia
Jl. Salemba Raya No. 6, Jakarta Pusat 10430, Telp. : (021) 3154175 Fax : (021) 31907911 Email : mapanik@yahoo.com

Nomor : 096/Red-MPI/XI/2022. Jakarta, 30 November 2022.
Lampiran : -
Perihal : Pemberitahuan.

Kepada Yth.
Penulis Artikel di Majalah Patologi Indonesia

Dengan hormat,

Dalam rangka meningkatkan kualitas penerbitan Majalah Patologi Indonesia dan persiapan akreditasi pada tahun 2024, dengan ini diberitahukan bahwa terhitung mulai penerbitan tahun 2023 semua artikel yang akan dimuat diharuskan memakai bahasa asing, dalam hal ini yaitu bahasa Inggris.

Sehubungan dengan hal tersebut, mohon kiranya Saudara dapat mengalihbahasakan artikel yang sudah siap untuk di-*lay out* dari bahasa Indonesia menjadi bahasa Inggris seluruhnya. Batas waktu pengiriman artikel yang sudah dalam bentuk bahasa Inggris adalah maksimal 31 Desember 2022.

Atas perhatian dan bantuan serta kerjasama yang baik, diucapkan terima kasih.

Majalah Patologi Indonesia,

Dr. Drs. Kusmardi, MS.
Pemimpin Redaksi.

Bukti Submit Perubahan Bahasa (3 Januari 2023)

5/10/23, 6:34 PM

Sriwijaya University Mail - Perubahan Penggunaan Bahasa pada Artikel MPI



Krisna Murti unsri <krisna.arinafril@unsri.ac.id>

Perubahan Penggunaan Bahasa pada Artikel MPI

Krisna Murti unsri <krisna.arinafril@unsri.ac.id>
To: mpi iapi <mpi.iapi@gmail.com>


Tue, Jan 3, 2023 at 7:36 AM

Kepada YTH:
Redaksi majalah patologi indonesia
Departemen Patologi Anatomi FK Universitas Indonesia
Jakarta

Dengan hormat,

Bersama ini saya kirimkan kembali manuskrip M. Bima Zulfikar yang telah di alihbahasakan ke dalam bhs Inggris.
Mohon saran.

Terimakasih
Krisna Murti
[Quoted text hidden]

 **M.BimaZ-KepadatanMicrovesselPadaLingkunganMikroTumorLimfomaHodgkin.docx**
395K

CORRELATION OF MICROVESSEL DENSITY WITH HISTOPATHOLOGICAL FEATURES OF HODGKIN LYMPHOMA

M. Bima Zulfikar¹, Krisna Murti², Iche Andriyani Liberty³, Citra Dewi², Riana Sari Puspita Rasyid⁴

¹Medical Undergraduate Study Program, ²Department of Anatomic Pathology, ³Department of Public Health, ⁴Department of Histology Faculty of Medicine, Universitas Sriwijaya Palembang

Received: 31-01-2022
Accepted: 10-02-2022
Published: 02-01-2023

Corresponding author: dr. Krisna Murti, M. Biotech. Stud., Ph.D., SpPA(K)
Department of Anatomic Pathology, Faculty of Medicine, Universitas Sriwijaya
Jl. Jenderal Sudirman Km. 3½, Palembang 30126.
e-mail: krisna.arinafril@unsri.ac.id

ABSTRAK

Latar belakang

Angiogenesis ialah proses pembentukan pembuluh darah baru yang berperan penting dalam perkembangan sel tumor. Penilaian kepadatan *microvessel/microvessel density* (MVD) merupakan salah satu metode yang digunakan dalam menilai angiogenesis. Nilai kepadatan *microvessel* tinggi berkaitan dengan prognosis yang buruk pada berbagai jenis kanker termasuk limfoma Hodgkin (LH). Meskipun insiden LH cenderung lebih rendah di negara berkembang, namun tingkat kematiannya cenderung tinggi. Limfoma ini banyak terjadi pada usia muda reproduktif. Tujuan penelitian ini untuk mengetahui hubungan kepadatan *microvessel* dengan karakteristik klinikohistopatologi LH.

Metode

Penelitian analitik observasional dengan metode potong lintang dilakukan dengan sampel penelitian berupa blok parafin pasien yang didiagnosis sebagai limfoma Hodgkin serta memiliki data klinikohistopatologi lengkap sesuai kriteria di Bagian Patologi Anatomi Fakultas Kedokteran Universitas Sriwijaya/RSUP. Dr. Mohammad Hoesin Palembang periode 2016-2021. Slain dipulas dengan antibodi anti-CD34. Satu *microvessel* dinilai dengan mengamati morfologi sitoplasma dan/atau membran sel endotel berwarna coklat setelah dipulas oleh anti-CD34. Hasil perhitungan kepadatan *microvessel* dianalisis secara statistik menggunakan STATA versi 15.

Hasil

Kejadian limfoma Hodgkin pada penelitian ini cenderung banyak pada kategori usia <45 tahun (71,00%), laki-laki (61,30%), berlokasi di nodal (80,60%) dan subtype *lymphocyte rich classical HL* (LRCHL, 51,60%). Meskipun didapatkan hubungan yang tidak signifikan antara kepadatan *microvessel* dengan karakteristik klinikohistopatologi LH, namun terlihat distribusi kepadatan *microvessel* tinggi cenderung pada kelompok usia <45 tahun, laki-laki, lokasi di nodal, dan pada subtype LRCHL.

Kesimpulan

Terdapat hubungan yang tidak signifikan antara kepadatan *microvessel* dengan karakteristik klinikohistopatologi limfoma Hodgkin.

Kata kunci: Limfoma Hodgkin, kepadatan *microvessel*, angiogenesis, CD34, karakteristik klinikohistopatologi.

Correlation of Microvessel Density with Histopathologic Features of Hodgkin Lymphoma ABSTRACT**Background**

Angiogenesis is the process of new blood vessel growth that has an important role in tumor development. Microvessel density (MVD) assessment is one of the methods to assess angiogenesis. A high MVD is associated with a poor prognosis in various types of cancer including Hodgkin lymphoma (HL). Although, HL incidence is lower in developing countries, the death rate is higher in these regions. Moreover, this type of lymphoma is higher among young and reproductive people. The aim of this study was to determine the association between micro vessel density and HL clinicohistopathological characteristics.

Methods

The observational analytic study with a cross-sectional method was conducted at the Anatomical Pathology Department/Dr. Mohammad Hoesin Palembang. The samples were paraffin blocks diagnosed as HL for period 2016-2021 and has complete clinicohistopathological data according to the criteria of this study. The slides were immunostained with antibody anti-CD34. One microvessel was determined by observing the endothelial morphology and CD34 expression in endothelial cytoplasm and/or cell membrane, then was evaluated and calculated by ImageJ. Data was statistically analyzed by STATA version 15.

Results

Majority HLs in this study were discovered in the age group of <45 years (71.00%), male (61.30%), nodal location (80.60%) and lymphocyte rich classical HL (LRCHL) subtype (51.60%). Although, there was no significant association between MVD and the clinicohistopathological characteristics of HL, high MVD tend to occur in the age <45 years, male, nodal location, and LRCHL subtype.

Conclusion

There was no significant association between microvessel density and HL clinicohistopathological characteristics.

Keywords: hodgkin lymphoma, microvessel density, angiogenesis, CD34, clinicohistopathological characteristics.

INTRODUCTION

A large cluster of neoplasms derived from the immune system is known as a lymphoma. Ninety percent of lymphoma derives from lymphocyte B cells, while the rest is from lymphocyte T cells and natural killer (NK) cells. 1 Based on the existence of the Hodgkin cell, lymphoma is classified as either Hodgkin or non-Hodgkin lymphoma. Non-Hodgkin lymphoma accounts for 80–85% of all lymphoma cases, while Hodgkin lymphoma accounts for 10–15%. 2 Hodgkin lymphoma was the world's 27th most common malignancy, with 83,087 new cases and 23,376 deaths. 3

The incidence of Hodgkin lymphoma tends to be higher in developed countries than in developing countries. Meanwhile, the mortality rate is relatively high in developing countries. 4 Hodgkin lymphoma is often found within the 15–30-year-old range and increases in age beyond 55 years old. 5 Except for the NSCHL subtype, which has the same incidence ratio in men and women, it has a greater predilection in men. 6

Hodgkin lymphoma is characterized by Reed-Sternberg cells, which are large cells with a multi-lobed nucleus, a prominent nucleolus, and wide and slightly eosinophilic cytoplasm that resembles an owl's eye. 7 Around 90% of Hodgkin lymphoma is classical Hodgkin lymphoma (CHL), and 10% or less is nodular lymphocyte predominant Hodgkin lymphoma (NSCHL), which is often found in developed countries and dominated by young adults. Meanwhile, the mixed-cellularity classical Hodgkin lymphoma (MCCHL) subtype is found in children from developing countries. The lymphocyte-depleted classical Hodgkin lymphoma (LDCHL) subtype has the worst prognosis, while the lymphocyte-rich classical Hodgkin lymphoma (LRCHL) has a better prognosis compared with other subtypes. 1

Many studies have found that angiogenesis, which supplies oxygen from the circulatory system to tumor cells so that they can grow, is frequently found in tumor development. 9 Angiogenesis is the formation of new blood vessels, which are important in the growth of tumors and metastasis. At first, tumor cells obtain oxygen through diffusion. The increased number of tumor cells caused diffusion to no longer supply enough oxygen for tumor growth. This condition triggers the response of tumor and stromal cells in the microtumor environment to release proangiogenic factor, which stimulates the proliferation and migration of endothelial cells in the formation of new blood vessels. 10

Angiogenesis is assessed by measuring microvessel density (MVD), which can be considered in predicting prognosis. It is believed that high-density microvessels are related to poor prognosis in many types of cancer. 11 A previous study found that increased angiogenesis and microvessel density were associated with a poor prognosis in CHL. 12 Inhibition of angiogenesis activity with anti-angiogenic therapy is expected to inhibit the growth and metastasis of tumors. Therefore, anti-angiogenic therapy can be one of the treatment choices for Hodgkin lymphoma. 13

In Indonesia, there have been few studies on the relationship between microvessel density and clinicopathological features of Hodgkin lymphoma. Furthermore, similar studies in other countries showed different results, which is the reason for the author to conduct this study. The results of this study are expected to be beneficial as a prognostic marker and aid in determining antiangiogenic therapy as an effective adjuvant therapy for Hodgkin lymphoma in the future.

METHODS

This study used a cross-sectional observational analytic design, was conducted in the Department of Anatomical Pathology in the Faculty of Medicine of Sriwijaya University/RSUP Dr. Mohammad Hoesin Palembang. The population included all cases

diagnosed pathologically as Hodgkin lymphoma during 2016-2021. Samples were obtained through non-probability sampling, namely the purposive sampling technique.

The samples were part of the population that fulfilled the inclusion and exclusion criteria. The inclusion criteria included an archive of hematoxylin-eosin (HE) and immunohistochemistry (IHC) preparations and a paraffin block diagnosed as Hodgkin lymphoma with complete medical record data including age, gender, tumor location, and subtype. The exclusion criteria included archives of HE preparations and paraffin blocks with signs of cell damage due to inadequate fixation, and the paraffin block did not contain enough tumor tissue for IHC examination using anti-CD34 antibodies and recurrent cases. There were 31 samples that fulfilled the criteria.

Observation and measurement of microvessels were carried out using an Olympus BX51 binocular light microscope equipped with a DP-21 digital camera. The images from the camera were analyzed and measured with the Image J software. Microvessels were identified by observing single or clustered endothelial cells that were separated from the surrounding tumor cells and stained brown by an anti-CD34 antibody with or without a lumen; each blood vessel did not have more than eight erythrocytes inside the lumen; each blood vessel did not have a muscle layer; and it was not located in the sclerotic area. 14,17 Figure 4.1 depicts an identified microvessel structure (black arrow).

Microvessel density was assessed by choosing three areas with the densest microvessel in a small field of view (100x), then choosing the five densest areas in a large field of view (400x). Afterward, the mean value was calculated by adding the results of the five areas above, divided by 5 in each sample. The collected data were statistically analyzed using STATA software version 15 to determine the clinicohistopathological characteristics distribution of Hodgkin lymphoma, as well as the correlation between microvessel density and clinicohistopathological characteristics using Chi-Square and a significant result of $p < 0.05$.

RESULTS

Microvessel Morphology

Identifying a microvessel microscopically is carried out by paying attention to the following characteristics: (1) single or clustered endothelial cells separated from the surrounding tumor cells and stained brown by anti-CD34 with or without a lumen; (2) each blood vessel does not contain more than eight erythrocytes inside the lumen; (3) each blood vessel does not have a muscle layer; (4) the blood vessel is not located in a sclerotic area. 14,27 Figure 1 shows an identified microvessel structure (black arrow).

Clinicohistopathological Characteristics of Hodgkin Lymphoma

The age range in this study was 7-77 years old, with an average age of 36 years old. Patients aged <45 years old had more diagnoses of Hodgkin lymphoma, comprising 22 samples (71.0%). There were more men than women, comprising 19 samples (61.30%). Nodal locations were seen more often in 25 samples (80.60%). The LRCHL subtype, with 16 samples (51.60%), was the most common (Table 1).

Table 1. Clinicohistopathological characteristics distribution of Hodgkin lymphoma.

Clinicohistopathological characteristics	Number	Frequency
	n	%
Age		
<45y.o.	22	71.00
≥45y.o.	9	29.00
Gender		
Men	19	61.30
Women	12	38.70
Tumor location		
Nodal	25	80.60
Extranodal	6	19.40
Subtype		
NSCHL	6	19.40
MCCHL	9	29.00
LDCHL	0	0.00
LRCHL	16	51.60

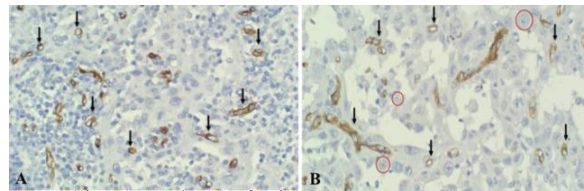


Figure 1. Immunohistochemistry staining with anti-CD34 antibody. A. High microvessel density in the tumor microenvironment (black arrow); B. Low microvessel density in the tumor microenvironment (black arrow). 400x magnification.

Distribution of Microvessel Density in Hodgkin Lymphoma

The distribution of microvessel density in Hodgkin lymphoma is divided into two categories: high microvessel density and low microvessel density. The Shapiro-Wilk test was conducted beforehand and revealed normally distributed microvessel density data ($p > 0.05$). Because the data is normally distributed, the mean value is considered the cut-off value. The mean value of microvessel density is 18.26 and it is determined as the cut-off value, where microvessel density above 18.26 is considered high and density below 18.26 is considered low (Table 2).

Table 2. Distribution of microvessel density in Hodgkin lymphoma.

	Mean	Std. Deviation	Min	Max	p
Microvessel density	18.26	5.47	10.40	32.10	0.13

Correlation between Microvessel Density and Clinicohistopathological Characteristics of Hodgkin Lymphoma

There is a statistically insignificant correlation between microvessel density and clinicohistopathological characteristics of Hodgkin lymphoma (age, gender, tumor location, subtype) ($p > 0.05$). However, high microvessel density tends to be occurred in the 45-year-old age group ($p = 0.60$), men ($p = 0.88$), nodal location ($p = 0.08$), and LRCHL subtype ($p = 0.84$) as seen in Table 3.

Table 3. Correlation between microvessel density and clinicohistopathological characteristics of Hodgkin lymphoma.

Clinicohistopathological characteristics	Microvessel density		P value
	High	Low	
Age			
<45 y.o.	10	12	0.60
≥45 y.o.	5	4	
Gender			
Men	9	10	0.88
Women	6	6	
Tumor location			
Nodal	14	11	0.08
Extranodal	1	5	
Subtype			
LRCHL	7	9	0.84
LDCHL	-	-	
MCCHL	5	4	
NSCHL	3	3	

DISCUSSION

Angiogenesis is the process of new blood vessel tissue formation that is important in the growth of tumors and metastasis. Angiogenesis is a response of tumor cells and stroma cells in the tumor microenvironment in releasing pro-angiogenic factor that stimulates the proliferation and migration of endothelial cells (ECs) required in forming new blood vessels.¹⁰ One of the methods to quantify new blood vessels inside tumor tissues is by measuring microvessel density (MVD) with immunohistochemistry (IHC) staining.¹¹ This study used anti-CD34 as a microvessel marker.¹⁴ A recent study indicated that microvessel density can be used to predict the prognosis of lymphoma because high microvessel density is correlated with a poor prognosis in CHL cases.¹²

Age is an important factor in predicting the overall prognosis and is an independent factor to assess progression-free survival in Hodgkin lymphoma patients.¹⁵ The age distribution of Hodgkin lymphoma patients varies according to ethnicity and socioeconomic status in a region. In general, Hodgkin lymphoma often occurs in patients aged 15–30 years and older than 55 years.¹⁶ The patients' age in this study is around 7–77 years old (mean age of 36.32 years). The youngest age in this study was younger than the study by Hewamana et al., who had an age interval of 12–83 years old.¹⁷ This may be because, in developing countries, Hodgkin lymphoma is more often found in children.⁸

Analysis of the correlation between microvessel density and age in this study showed a statistically insignificant correlation ($p = 0.60$). However, high microvessel density was most likely found in patients younger than 45 years old. This is in line with Koh et al., who studied the correlation between clinicopathological characteristics and microvessel density and stated that there is no significant correlation between age and microvessel density ($p = 0.56$), with a similar tendency of high microvessel density in the <45-year-old age group.¹⁸ There is a decrease in HIF-1 expression and angiogenic factors such as VEGF in elderly patients, as well as changes in the extracellular matrix in the tumor microenvironment. Meanwhile, in the angiogenesis process triggered by hypoxic conditions in tumor tissues, this HIF-1 expression is required to induce various angiogenic factors such as VEGF. Therefore, microvessel density is usually lower in older patients and higher in younger patients.^{19–21}

In this study, Hodgkin lymphoma is more often found in men (61.30%) compared to women (38.70%), with a ratio of 1.6:1. This is in line with an epidemiologic study by the WHO, which stated that Hodgkin lymphoma is more often found in men.¹ This study also confirms the findings of Wen-Yan Yu, et al., who obtained a ratio of Hodgkin lymphoma incidence of 1.67:1 between men and women.²²

Statistical analysis indicated an insignificant correlation between microvessel density and gender ($p = 0.88$), with a tendency for higher microvessel density in men compared to women. This is in line with Panico et al. and Makboul et al., who stated that there is no statistically significant correlation between gender and microvessel density.^{23,24} Koh et al. also suggested a similar tendency for high microvessel density in men ($p = 0.07$).¹⁸ This is due to higher androgen levels in men compared to women. Androgen improves the angiogenesis process through an increased response of proliferation and migration of endothelial cells by inducing the regulation of genes related to angiogenesis, such as HIF-1 α and SDF-1 α , and pro-angiogenic factors such as VEGF and VEGFR.^{25,26}

Almost all Hodgkin lymphoma cases are found in the lymph nodes. Therefore, this disease is also known as a nodal disease. Hodgkin lymphoma can also develop to infiltrate the spleen, liver, and other extranodal locations.⁸ In this study, Hodgkin lymphoma is more often found in nodal (80.60%) compared with extranodal locations (19.40%). Statistical

analysis revealed an insignificant correlation between tumor location and microvessel density ($p = 0.08$), with a tendency for high microvessel density in nodal locations. This result is in line with a study conducted on mantle cell lymphoma, which stated that there is no significant correlation between tumor location and microvessel density.²⁷

The LRCHL subtype is the most common subtype of Hodgkin lymphoma in this study, which comprises 16 cases (51.60%). This is different from Konkay et al.'s study in India, which found the MCCHL subtype as the most frequently found Hodgkin lymphoma subtype. The same also applies to a study in developing countries that found that MCCHL is the most common subtype of Hodgkin lymphoma.^{28,29} High MCCHL subtype is related to HIV and is often related to a poor prognosis.³⁰ On the other hand, the LRCHL subtype is often related to a better prognosis compared to other subtypes.³¹ Makboul et al. discovered a significant correlation between microvessel density and a high histological subtype of MCCHL.²⁴ However, statistical analysis in this study revealed an insignificant correlation between subtype and microvessel density ($p = 0.84$). This is in line with Koh et al., who stated that there is no significant correlation between disease subtype and microvessel density ($p = 0.31$).¹⁸

There is no study investigating the correlation between microvessel density and clinicohistopathological characteristics of Hodgkin lymphoma in Indonesia. To date, more studies are needed on the correlation between microvessel density and clinicohistopathological characteristics of Hodgkin lymphoma, including age, gender, tumor location, and subtype. Considering differences between this study and previous studies, especially the most frequently found subtype, microvessel density can be related to the patient's outcome, as with other cancer types such as non-Hodgkin lymphoma, colon cancer, cervical cancer, and prostate cancer.³²⁻³⁵ Further studies with a more complete and larger sample of data are needed to prove the above possibility.

CONCLUSION

This study does not find any significant correlation between microvessel density and clinicopathological characteristics (age, gender, tumor location, and subtype) in Hodgkin lymphoma. Further studies are suggested to determine the role of microvessel density as a prognostic factor using patient outcome data such as progression-free survival and overall survival.

REFERENCES

1. Swerdlow SH, Campo E, Harris NL, Jaffe ES, Pileri SA, Stein H, *et al.* WHO Classification of Tumours of Haematopoietic and Lymphoid Tissues. 4th ed. Lyon, France: International Agency for Research on Cancer (IARC); 2017. 423-41 p.
2. Wang L, Qin W, Huo YJ, Li X, Shi Q, Rasko JEJ, *et al.* Advances in targeted therapy for malignant lymphoma. *Signal Transduct Target Ther* [Internet]. 2020;5(1). Available from: <http://dx.doi.org/10.1038/s41392-020-0113-2>
3. Sung H, Ferlay J, Siegel RL, Laversanne M, Soerjomataram I, Jemal A, *et al.* Global Cancer Statistics 2020: GLOBOCAN Estimates of Incidence and Mortality Worldwide for 36 Cancers in 185 Countries. *CA Cancer J Clin.* 2021;71(3):209-49.
4. Ferlay J, Ervik M, Lam F, Colombet M, Mery L, Piñeros M, *et al.* Global Cancer Observatory: Cancer Today. *Int Agency Res Cancer* [Internet]. 2020;68(6):3-4. Available from: <https://gco.iarc.fr/today>
5. Crombie JL, LaCasce AS. Current considerations in AYA Hodgkin lymphoma. *Br J Haematol.* 2019;184(1):72-81.
6. Hudnall SD. Pathology of Hodgkin Lymphoma. In: Cagle PT, editor. *Precision*

- Molecular Pathology of Hodgkin Lymphoma [Internet]. Switzerland, AG: Springer Nature; 2018. p. 13-34. Available from: <https://doi.org/10.1007/978-3-319-68094-1-2>
7. Kumar V, Abbas AK, Aster JC. Robbins Basic Pathology. 10th ed. Elsevier. Philadelphia, Pennsylvania: Elsevier; 2018. 474-6 p.
 8. Piris MA, Medeiros LJ, Chang KC. Hodgkin lymphoma: a review of pathological features and recent advances in pathogenesis. *Pathology*. 2020;52(1):154-65.
 9. Lugano R, Ramachandran M, Dimberg A. Tumor angiogenesis: causes, consequences, challenges and opportunities. *Cell Mol Life Sci* [Internet]. 2020;77(9):1745-70. Available from: <https://doi.org/10.1007/s00018-019-03351-7>
 10. Lopes-coelho F, Martins F, Pereira SA. Anti-Angiogenic Therapy: Current Challenges and Future Perspectives. *Int J Mol Sci*. 2021;22(7):3765.
 11. Zhang Q, Wu J, Bai X, Liang T. Evaluation of intra-tumoral vascularization in hepatocellular carcinomas. *Front Med*. 2020;7:1-9.
 12. Menzel L, Höpken UE, Rehm A. Angiogenesis in lymph nodes is a critical regulator of immune response and lymphoma growth. *Front Immunol*. 2020;11:1-25.
 13. Filipiak J, Boińska J, Rość D. Angiogenesis in Hodgkin's lymphoma. *Med Res J*. 2018;2(3):83-8.
 14. Agnani B, Solanki R, Ansari M, Agnani S. Prognostic Significance of Microvessel Density as Assessed by anti CD34 Mono-clonal Antibody in Invasive Ductal Carcinoma of Breast. *Asian Pac J Cancer Biol*. 2020;5:75-9.
 15. Cuccaro A, Bartolomei F, Cupelli E, Galli E, Giacheli M, Hohauser S. Prognostic factors in Hodgkin lymphoma. *Mediterr J Hematol Infect Dis*. 2014;6(1):e2014053.
 16. Hjalgrim H, Jarrett RF. Epidemiology of Hodgkin Lymphoma. In: Engert A, Younes A, editors. *Hematologic Malignancies: Hodgkin Lymphoma A Comprehensive Update on Diagnostics and Clinics*. 3rd ed. Switzerland, AG: Springer Nature; 2020. p. 4-18.
 17. Hewamana S, Kandabadge L, Skandarajah T, Peiris N. E-Clinical Medicine Applicability of protocols from high-income countries in a resource limited setting; real world data of histopathology, clinical features and long-term outcome of Hodgkin Lymphoma in Sri Lanka. *E-Clinical Medicine* [Internet]. 2021;38:100998. Available from: <https://doi.org/10.1016/j.eclinm.2021.100998>
 18. Koh YW, Park C, Yoon DH, Suh C, Huh J. CD163 expression was associated with angiogenesis and shortened survival in patients with uniformly treated classical Hodgkin lymphoma. *PLoS One*. 2014;9(1):e87066.
 19. Aboukhouzam R, Brodaczewska K, Filipiak A, Zeinelabdin NA, Buart S, Szczylik C, *et al*. Tumor hypoxia regulates immune escape/invasion: Influence on angiogenesis and potential impact of hypoxic biomarkers on cancer therapies. *Front Immunol*. 2021;11.
 20. Lv X, Li J, Zhang C, Hu T, Li S, He S, *et al*. The role of hypoxia-inducible factors in tumor angiogenesis and cell metabolism. *Genes Dis* [Internet]. 2017;4(1):19-24. Available from: <http://dx.doi.org/10.1016/j.gendis.2016.11.003>
 21. Moriya J, Minamino T. Angiogenesis, Cancer, and vascular Aging. *Front Cardiovasc Med*. 2017;4:1-7.
 22. YU W-Y, Geng M, Hao J, Chan M, SU-Jiang Zhang. Clinical features and prognosis analysis of Hodgkin's lymphoma: A multicenter retrospective study over a decade of patients in China. *Clin Lymphoma Myeloma Leuk*. 2017;17(5):274-82.
 23. Panico L, Ronconi F, Lepore M, Tenneriello V, Cantore N, Carmela A, *et al*. Prognostic role of tumor-associated macrophages and angiogenesis in classical Hodgkin lymphoma. *Leuk Lymphoma*. 2013;54:2418-25.
 24. Makboul R, Refaiy A, Mohamed R, Attia A, Osama D, Emary AN, *et al*. Impact of Cox2, CD163, and microvessel density expression on the prediction of relapse and

- patients' outcome in classical Hodgkin lymphoma. *Middle East J Cancer*. 2021;
25. Lam YT, Lecce L, Yuen SC, Wise SG, Handelsman DJ, Karas RH, *et al*. Androgens ameliorate impaired ischemia-induced neovascularization due to aging in male mice. *Endocrinology*. 2019;160:1137-49.
 26. Abi-ghanem C, Robison LS, Zuloaga KL. Androgens effects on cerebrovascular function in health and disease. *Biol Sex Differ*. 2020;11(35).
 27. Veselá P, Tonar Z, Šálek D, Vokurka S, Trněný M, Kodet R, *et al*. Microvessel density of mantle cell lymphoma. A retro-spective study of its prognostic role and the correlation with the Ki-67 and the mantle cell lymphoma international prognostic index in 177 cases. *Virchows Arch*. 2014;465:587-97.
 28. Konkay K, Paul TR, Uppin SG, Rao DR. Hodgkin lymphoma: A clinicopathological and immunophenotypic study. *Indian J Med Paediatr Oncol*. 2016;37:59-65.
 29. Shanbhag S. Hodgkin Lymphoma: A review and update on recent progress. *CA Cancer J Clin*. 2018;68:116-32.
 30. Adam M, Bekueretsion Y, Abubeker A, Tadesse F, Kwiecinska A, Howe R, *et al*. Clinical characteristics and histopathological patterns of Hodgkin lymphoma and treatment outcomes at a tertiary cancer center in Ethiopia. *JCO Glob Oncol*. 2021;:277-88.
 31. Wang HW, Balakrishna JP, Pittaluga S, Jaffe ES. Diagnosis of Hodgkin lymphoma in the modern era. *Br J Haematol*. 2019;184:45-59.
 32. Hu X, Liu H, Ye M, Zhu X. Prognostic value of microvessel density in cervical cancer. *Cancer Cell Int* [Internet]. 2018;18(1):1-12. Available from: <https://doi.org/10.1186/s12935-018-0647-3>
 33. Wu J, Ma S, Sun L, Qin Z, Wang Z, Wang N, *et al*. Prognostic value of microvessel density in non-Hodgkin lymphoma: A Meta-Analysis. *Acta Haematol*. 2021;144(6):603-12.
 34. Den Uil SH, Van Den Broek E, Coupé VMH, Vellinga TT, Delis-Van Diemen PM, Brill H, *et al*. Prognostic value of microvessel density in stage II and III colon cancer patients: A retrospective cohort study. *BMC Gastroenterol*. 2019;19:1-9.
 35. Jiang Z, Feng G, Wang K. Microvessel density as a prognostic indicator of prostate cancer: A systematic review and meta-analysis. *Open Med*. 2021;16:882-91.