

Relationship_between_Retinal_Nerve_Fiber_Layer....pdf

by Ramzi Amin1

Submission date: 06-Sep-2019 12:18PM (UTC+0700)

Submission ID: 1168045566

File name: Relationship_between_Retinal_Nerve_Fiber_Layer....pdf (280.64K)

Word count: 2921

Character count: 14403

Original Article

Relationship between Retinal Nerve Fiber Layer with Visual Field Defect in Non Proliferative Diabetic Retinopathy

Ilfurqon, Ramzi Amin, AK Ansyori

Department of Ophthalmology, Faculty of Medicine, Universitas Sriwijaya
M. Hoesin Hospital, Palembang, South Sumatera

ABSTRACT

Background: In the early stages of diabetic retinopathy, neuronal abnormalities include changes in ganglion cell death. Neuronal apoptosis is suspected as one of the causes responsible for the occurrence of lesions at an early stage of diabetic retinopathy, which results in a decrease in number of ganglion cells and thinning of the layer of ganglion cells, which can be caused by several mechanisms including glutamate excitotoxicity, oxidative stress, hyperglycemia, and neuroinflammation. Retinal ganglion cell death and axonal degeneration, will cause thinning of the retinal nerve fiber layer (RNFL) which may result in decrease in neural function, which in turn have an impact on the occurrence of visual field defects. This study is to determine the relationship between the thickness of RNFL with visual field defects in patients with non-proliferative diabetic retinopathy (NPDR).

Methods: This study is a comparative analytic cross-sectional design with sample of 66 eyes of 34 people in clinic of retina subdivision of Moh. Hoesin Hospital Palembang from July to November 2013. Patients of NPDR examined fundus photo, Oculo Coherence Tomograph and Humphrey Field analyzer.

Results: RNFL thickness average in this study is $104.4 \pm 10.9 \mu\text{m}$. Visual field defect occur in moderate and severe NPDR.

Conclusion: There is a strong relationship between RNFL thickness with visual field defects in patients NPDR ($r = -0.693$).

Keywords: RNFL thickness, visual field defect, NPDR

Diabetes mellitus (DM) is a disease that needs to wary in Indonesia. Projected worldwide epidemic with diabetes increased by 46% from 151 million people in 2010. Approximately 40% of cases of diabetes are at risk of diabetic retinopathy (DR), even 8% threatened with blindness.¹ World Health Organization (WHO) reported that Indonesia ranks number four countries with the highest DM.¹

Several studies have shown that not only the vascular abnormalities but also abnormalities

of neuronal, including the death of retinal ganglion cells, pathogenic changes occur in the early stage DR. Both of these factors need to be considered in the pathogenesis of DR, so that the vascular and neuronal abnormalities examination at an early stage can be a reference DR which can help determine the mechanism of the DR.^{2,3,4}

Some studies have also suggested that the DM resulted in apoptotic cells in the retina, particularly neuronal cells. Neuronal apoptosis is

supposed as one of the causes responsible for the occurrence of lesions at an early stage DR, which resulted in a decrease in the number of ganglion cells and thinning of the layer of ganglion cells, inner and outer plexiform layer.⁵ Apoptosis of neuronal cells in the retina in patients with DR can be caused by several mechanisms, among others glutamate excitotoxicity, oxidative stress, hyperglycemia, and neuroinflammation.^{1,3,4,6}

Retinal ganglion cell death and axonal degeneration will lead to depletion of the retinal nerve fiber layer (RNFL). In early-stage DR, area of RNFL appear thinner in DM patients than them without DR. Neuronal abnormalities at an early-stage DR is difficult to be observed and evaluated by routine examination, but an ophthalmologist should be aware of the condition of retinal ganglion cells when evaluating the condition of the eye with DR. It is important because the retinal neurons is irreversible and does have direct impact on visual function. RNFL thinning may result in a function decrease of neurons which in turn have an impact on the occurrence of visual field defects.^{6,7}

Because of the small number of studies evaluating the mechanism of DM against neuro-retinal degeneration, there has been no research on the relationship between RNFL thinning in DR patients and visual field defects. Researcher is interested in evaluating the relationship between RNFL thickness in the area of DR peripapillary in patients using Stratus OCT and its relationship with the incidence of visual field defects using the Humphrey Field Analyzer.

METHODS

This study is an analytical cross-sectional comparative design to determine the relationship between the thickness of the retinal nerve fiber layer with visual field defects in NPDR patients at Retina Subdivision of Eye Clinic M. Hoesin Hospital, Palembang. Overall execution time started from July 2013 to January 2014. Inclusion criteria were the non-proliferative diabetic retinopathy patients and the results of intraocular pressure were <21 mmHg; while exclusion criteria were 1) patients with abnormalities other than non-proliferative diabetic retinopathy disorders; 2) glaucoma

patients with optic neuropathy that states disorder accompanied by visual field defects with intraocular pressure as a risk factor; 3) NPDR patients who can not be examined with OCT and Humphrey Field Analyzer or as uncooperative or inadequate scan results; 4) patients did not will to follow the study expressed by signing a letter of approval on the basis of awareness (informed consent). In this study, the sample selection method used consecutive sampling.

All study subjects were performed anamnesis, clinical & physical examination, laboratory tests, and funduscopy examination. Measuring instruments being used were Fundus Photo Zeiss Visucam NM/FA, Zeiss Stratus Optical Coherence Tomography, and Zeiss Humphrey Field Analyzer.

Following is the RNFL thickness expressed in μm :

Table 1. Data distribution of subjects based on the thickness of the neural abnormalities, including the death of RNFL

Quadrant	Average thickness of RNFL (μm)	SE
Temporal	75.79±13.03	2.07
Superior	133.46±16.71	2.7
Nasal	87.57±16.85	2.7
Inferior	143.59±19.89	3.08
Mean	110.10±12.81	2.08

RESULT

This study was conducted from July 2013 to January 2014 at the Retina Subdivision of Eye Clinic, M. Hoesin Hospital, Palembang. The sample size meets the acceptance criteria and participation in this study were 66 eyes of 34 patients with NPDR. There were two eyes that could not be examined with OCT and Humphrey Field Analyzer due to the mature cataract on one eye and proliferative diabetic retinopathy on the other one.

The average age of this study subjects was 54.11±10.06 years with most patients aged between 50-60 years; 14 subjects were male and 20 others were female. Based on the degree of NPDR from 34 subjects contained 66 eyes with details of 13 eyes (19.7%) with mild NPDR, 14 eyes with moderate NPDR, and 39 eyes with severe NPDR.

Table 2. Data distribution of subjects based on the thickness of the RNFL

Quadrant	Average thickness of RNFL (μm)	95% Confidence Interval
Superior	130.97 \pm 20.60	125.90 – 136.04
Inferior	131.92 \pm 23.04	126.26 – 137.59
Nasal	79.03 \pm 18.35	74.52 – 83.54
Temporal	75.8 \pm 17.56	71.53 – 80.17
Mean	104.4 \pm 10.91	101.73 – 107.09

Average Mean Deviation (MD) field of view with the Humphrey Field Analyzer examination was -7.3 ± 4.13 , while the distribution of subjects based on the Mean Deviation (MD) of Humphrey Field Analyzer to see the visual defects in 53 eyes with results outside the normal visual field was shown in the table 3.

Table 3. Data distribution of subjects based on the MD

Visual Field	Total	Mean
Out of normal	53 (80.3%)	-2.42 \pm 0.68
Normal	13 (19.7%)	-6.68 \pm 3.71
Total	66 (100%)	

On the results of this study, the test from McNewmart found no significant difference in terms of visual field defects among male and female patients with $p=0.14$ ($p<0.05$).

There was no significant difference in RNFL thickness between male patients and female with $p=0.262$ ($p>0.05$).

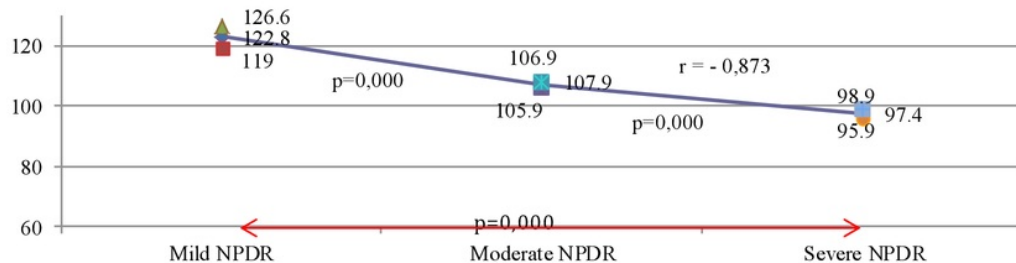
Average RNFL thickness appeared increasingly thinning on the subjects with severe NPDR compared with study subjects with mild and moderate NPDR. There was a very strong relationship between RNFL thickness with the degree of NPDR (Spearman's test: $r=-0.873$) were shown in chart 1 and table 4.

In this study, a strong correlation between the degree of non-proliferative diabetic retinopathy with visual field defects were expressed in MD ($r=0.611$, $p=0.000$). This means that the more severe NPDR degree, the greater the deviation from the reference MD group.

Statistical test results shown that patients with visual field defects had thinner RNFL thickness significantly compared with patients who did not have visual field defects ($p=0.000$, $p<0.05$).

Table 5. Data relationship between the average Mean Deviation (MD) degree visual field with a non-proliferative diabetic retinopathy

NPDR Criteria	Average Mean Deviation \pm SD
Mild degree	-2.42 \pm 0.68

**Chart 1.** Correlation between RNFL thickness with the degree of NPDR**Table 4.** Average thickness of RNFL in non-proliferative diabetic retinopathy patients

Quadrant	Mild	95% CI		Moderate	95% CI		Severe	95% CI	
		LL	UL		UL	LL		UL	LL
Temporal	83.4 \pm 14.6	74.5	92.3	78.7 \pm 15.2	69.9	87.5	74.0 \pm 17.8	66.3	78.3
Superior	153.3 \pm 14.7	144.7	162.4	135.0 \pm 18.9	124.1	145.9	122.0 \pm 16.5	116.6	127.4
Nasal	96.1 \pm 16.2	86.3	105.9	84.1 \pm 18.5	73.4	94.8	72.3 \pm 18.6	66.9	76.2
Inferior	158.8 \pm 21.8	145.7	171.8	130.1 \pm 18.9	119.2	141.0	123.6 \pm 17.9	117.9	129.4
Average RNFL	122.8 \pm 6.3	119.0	126.6	106.8 \pm 1.8	105.9	107.9	97.4 \pm 4.7	95.9	98.9

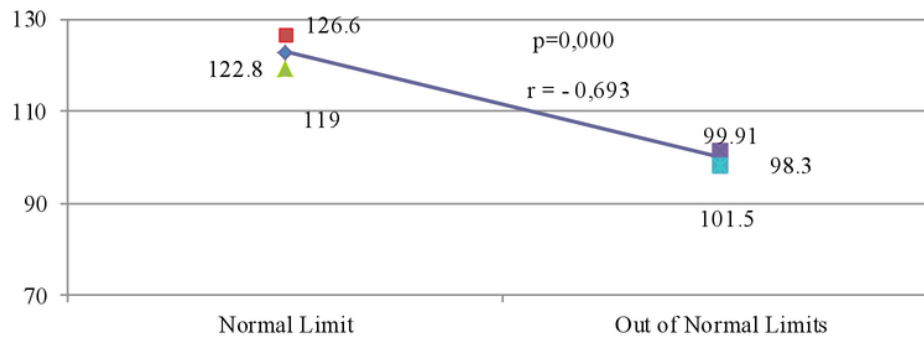


Chart 2. Relationship between average RNFL thickness with visual field

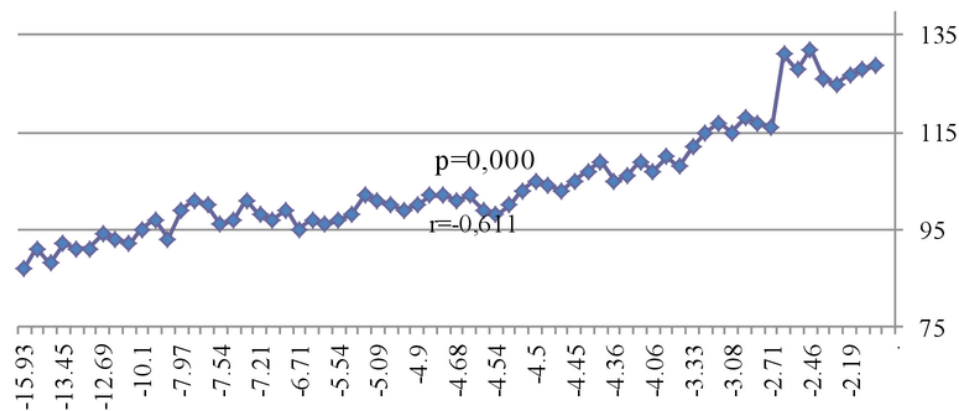


Chart 3. Relationship between average RNFL thickness with Mean Deviation (MD)

DISCUSSION

In this study, a strong correlation between RNFL thickness with field defects are expressed in MD ($r=0.611$, $p=0.000$). This means that the depletion of RNFL thickness, the deviation will occur greater MD than the reference group. This RNFL thinning occurs due to reduced population of ganglion cells because of apoptosis in the retina.

According to Jing Guangjun, J. Wang Joshua, and Sarah X. Zhang, NPDR would cause endoplasmic reticulum stress (ERS). This settled ERS, causing apoptosis of the retina, especially the retinal ganglion cells that have no myelin, resulting in a thinning of the RNFL.⁴ RNFL consists of ganglion cell axon. These axons run parallel to the surface of the

retina and optic disc then continue to exit the eye through the optic nerve lamina cribrosa. RNFL is a ganglion cell axons that collect visual impulse that begins from rod and cone cells to the optic disc. Thickest RNFL is seen mainly in the area peripapil and dwindling toward the ora serrata.⁹⁻¹³ The optic nerve carries the ganglion cell axons to the brain.

Rod and cone cells in the photoreceptor layer will change the light stimulus into a nerve impulse that is delivered by fiber layer of the retina through the optic nerve and finally to the brain visual cortex. Damage and dysfunction of the RNFL along the horizontal raphe will provide an overview of the visual field abnormalities in the form of defect or scotoma.

Previous research showed that there were variations in RNFL thickness, 110.10 ± 12.81

μm . Referring to these data, it is seen that the average RNFL thickness in all cases in this study was $104.4 \pm 10.91 \mu\text{m}$. However, further analysis indicated that there were significant RNFL thinning in moderate and severe NPDR but there is no depletion in mild NPDR. In patients with mild NPDR, RNFL thickness reach above the average value, 122.77 ± 6.26 . Whereas patients with moderate NPDR, RNFL thinning obtained an average, $106.86 \pm 1.74 \mu\text{m}$. Even in patients with severe NPDR, RNFL thinning reached $97.41 \pm 4.72 \mu\text{m}$.

In this study, thinning RNFL in the nasal and inferior quadrants in patients with moderate NPDR was visible; while in patients with severe NPDR, depletion occurred in all quadrants. RNFL thickness in mild NPDR patients was above average.

This study found that subjects with mild NPDR did not experience any scotoma or visual field defects, while subjects with moderate and severe NPDR earned any scotoma or visual field defects.

According to Oshitari T, Adachi K Hanawal and E-Usami, early-stage of DR will interrupt the RNFL. If we use the results of research by Asnagi et al as a benchmark, it is seen that RNFL thinning does not occur in patients with mild NPDR; while significant RNFL thinning occurs in moderate and severe NPDR. This is consistent with the theory that RNFL thinning occurs due to reduced population of ganglion cells.

Visual field defect or scotoma and RNFL thinning also occur in other disease such as glaucoma. The mechanism of RNFL thinning in glaucoma allegedly caused by direct pressure on axonal fibers due to increasing intraocular pressure that induces ganglion cell death. RNFL thinning in glaucoma is generally more common in the superior and inferior quadrants. This is presumably because the pathways of axons in the superior and inferior quadrants are longer than in the nasal and temporal, making it more susceptible to an increasing intraocular pressure.^{14,15}

Study by Nuzulul Aini obtained RNFL thinning in nasal quadrant. This is presumably because along with the increasing axial length of the eyeball, the retina would be stretched horizontally toward the temporal. This resulted in

the RNFL thinning in temporal region, solidifies and stretching of nerve fibers originate from the opposite side of the horizontal raphe (nasal side) so that the RNFL in the temporal quadrant became thick and in the nasal quadrant became thin.^{14,15}

REFERENCES

1. Purba DM, Hutaaruk JA, Elvioza, et al. Retina dari pediatrik hingga geriatrik. Cetakan I. Jakarta: Indonesia Printer; 2011.p.137-56
2. Hirozaku T, Tomomi G, Takuhei S, et al. Diabetes-associated retinal nerve fiber damage evaluated with scanning laser polarimetry. *Am J Ophthalmol* 2006;142:88-94
3. Kevin W, Bronson C, Marcus AB, et al. Early neural and vascular changes in adolescent type 1 and type 2 diabetic retina. *Retina* 2012;92-102
4. Oshitari T, Hanawa K, Usmani E. Changes of macular and RNFL thickness measured by stratus OCT in patients with early stage diabetes. *Eye* 2009;23:884-9
5. Barber A, Gardner T, Abcouwer S. The significance of vascular and neural apoptosis to the pathology of diabetic retinopathy. *Invest Ophthalmol Vis Sci* 2011;52:1156-63
6. Ratna S. Retinopati diabetik. [serial online] 2011;61:334-7, available from: URL: HYPERLINK <http://indonesia.digitaljournals.org>
7. Asnaghi V, Gerhardinger C, Hoehn T, Adeboje A, Lorenzi M. A role for the polyol pathway in the early neuroretinal apoptosis and glial changes induced by diabetes in the rat. *Diabetes* 2003;52:506-51
8. Leonard K, Naresh M, Malik Y. Comparison of retinal nerve fibre layer thickness in normal eyes using time-domain and spectral domain oculo coherence tomography. *Am J Ophthalmol* 2010;150:807-14
9. Oshitari T, Hata N, Yamamoto S. Endoplasmic reticulum stress and diabetic retinopathy. *Vascular Health and Risk Management* 2008;4(1):115-22
10. Mingyuan Wu, Shihe Yang, Michael H Elliot, et al. Oxidative and endoplasmic reticulum stresses mediate apoptosis induced by modified LDL in human retinal Müller cells. *Investigative Ophthalmology & Visual Science*, Juli 2012.
11. Chuanzhou Li, Leilei Wang, Kun Huang, et al. Endoplasmic reticulum stress in retinal vascular degeneration: protective role of resveratrol. *Invest Ophthalmol Vis Sci* 2012;53:3241-9
12. Bin Li, Dong Li, Gui-gang Li, et al. P58IPK inhibition of endoplasmic reticulum stress in human retinal capillary endothelial cells in vitro. *Molecular Vision* 2008;14:1122-8
13. Yimin Zhong, Jingming Li, Yanming Chen, et al. activation of endoplasmic reticulum stress by hyperglycemia is essential for Müller cell-derived inflammatory cytokine production in diabetes. *Diabetes* 2012;61:492-504
14. Aini Nuzulul. Korelasi antara derajat miopia aksial dan variasi ketebalan lapisan serabut saraf retina peripapil. Palembang: Departemen Ilmu Kesehatan Mata Fakultas Kedokteran Universitas Sriwijaya, 2011.
15. Shin HK, Seung WH, Seong KI, et al. Effect of myopia on the thickness of the retinal nerve fiber layer measured by Cirrus HD oculo coherence tomography. *Invest Ophthalmol Vis Sci* 2010;51(8):4075-83.

Relationship_between_Retinal_Nerve_Fiber_Layer....pdf

ORIGINALITY REPORT

8%

SIMILARITY INDEX

5%

INTERNET SOURCES

5%

PUBLICATIONS

3%

STUDENT PAPERS

PRIMARY SOURCES

1

robertpkolb.xyz

Internet Source

2%

2

Seibold, L.K.. "Comparison of Retinal Nerve Fiber Layer Thickness in Normal Eyes Using Time-Domain and Spectral-Domain Optical Coherence Tomography", American Journal of Ophthalmology, 201012

Publication

1%

3

www.tandfonline.com

Internet Source

1%

4

Submitted to Cardiff University

Student Paper

1%

5

E Adachi-Usami. "Changes of macular and RNFL thicknesses measured by Stratus OCT in patients with early stage diabetes", Eye, 04/25/2008

Publication

1%

6

pubmedcentralcanada.ca

Internet Source

1%

7

Submitted to University of Queensland

Student Paper

1%

8

"From the 16th International Neuro-ophthalmology Society (INOS) Congress 2006",
Neuro-Ophthalmology, 12/1/2006

Publication

1%

Exclude quotes On

Exclude matches < 1%

Exclude bibliography On