



Spinal Anesthesia in Patient with Congestive Heart Failure due to Congenital Atrial Septal Defect, and Pulmonary Hypertension Undergoing Cesarean Section Procedure: A Case Report

Anugerah Ade Periambudi^{1*}, Rizal Zainal², Mayang Indah Lestari³

¹Fellowship of Anesthesiology and Intensive Therapy, Faculty of Medicine, Universitas Sriwijaya, Indonesia

²Regional Anesthesia and Pain Management Division, Department of Anesthesiology and Intensive Therapy, Faculty of Medicine, Universitas Sriwijaya, Indonesia

³Intensive Care Division, Department of Anesthesiology and Intensive Therapy, Faculty of Medicine, Universitas Sriwijaya, Indonesia

***Corresponding author:**

Department of Anesthesiology
and Intensive Therapy
Faculty of Medicine,
Universitas Sriwijaya,
Palembang, Indonesia
Email: [anugerahadeperiambudi
@gmail.com](mailto:anugerahadeperiambudi@gmail.com)

ABSTRACT

Introduction. In patients suffering from heart disease, pregnancy is a risk factor for mortality. Heart disease in pregnant women can be in form of rheumatic heart disease, cardiomyopathy, or congenital heart disease. This case report is about the successful spinal anesthesia technique in cesarean section (C-section) patients with congestive heart failure due to congenital atrial septal defect, and pulmonary hypertension (PH).

Case presentation. A pregnant woman, 24 years old, planned to have an emergency C-section. She complained about shortness of breath for 2 days before admission. Three months ago, the patient started to feel shortness of breath during activity and also complained her legs swelled. She has a history of congenital heart i.e. atrial septal defect (ASD), but not routinely been treated. Her examination showed tachypnea, murmur, bibasilar fine crackles lung sound, and pretibial pitting edema. Echocardiography showed ASD with pulmonary hypertension. Spinal Anesthesia using 0.5% isobaric bupivacaine 7.5 mg and fentanyl 25 µg was given before surgery. Drugs was injected in L3-L4 level with the upper target was as high as T6. the head position is raised 30 degrees. Procedure went well and the APGAR score was 8/9, Patient was admitted to the ICU for one day and discharged from hospital at the 5 days of hospital care.

Conclusion. Spinal single-shot spinal anesthesia with small doses of bupivacaine and adjuvant can be used as an alternative technique in emergency C-section for patients with congestive heart failure due to congenital atrial septal defect, and pulmonary hypertension. **Keywords:** atrial septal defect, cesarean section, congestive heart failure, pulmonary hypertension



Introduction

Pregnancy increases the risk of maternal mortality in cardiac patients compared to the normal population. Except for patients with Eisenmenger syndrome, pulmonary obstructive disease, and Marfan syndrome with arthropathy, maternal death during pregnancy due to cardiac abnormalities is rare. Heart disease contributes 15% to maternal mortality and is closely related to heart function based on the New York Heart Association (NYHA) criteria. NYHA class I and II patients have a mortality rate of less than 1% while class III and IV patients have a mortality rate between 5% -15%. Although the maternal mortality rate is low, pregnant women with heart disease are at risk of suffering from diseases with other high morbidity rates such as heart failure, arithmetic, and stroke.⁶ Pregnant women with heart disease (high-risk pregnant patients) require multi-specialist treatment including obstetricians, cardiologists, and anesthesiologists. Heart disease in pregnant women can be Rheumatic heart disease, Cardiomyopathy, Congenital heart disease.⁵

Recent studies report the incidence of cardiac abnormalities in pregnant women of 0.1-4%. The largest group of 70% -80% consists of women with congenital heart disease who can reach adulthood due to surgical correction and drug therapy, then followed by a group of pregnant women with rheumatic heart disease. Although the incidence of heart disease has remained unchanged, the maternal mortality rate has declined from 6% in the 1930s to 0.5% -2.7% at present.⁶

There are several choices of anesthesia techniques for pregnant patients with cardiac disease undergoing cesarean section (C-section) including general anesthesia, epidural anesthesia. We report our successful case using spinal anesthesia technique in C-section patients with congestive heart failure due to congenital atrial septal defect, and pulmonary hypertension (PH).

Case Report

A 24-year-old woman from Palembang came to the Emergency Department with a complaint of pregnancy accompanied by continuously shortness of breath for three days. She felt more comfortable sleeping with 2 pillows. Since three months ago, she complained the shortness of breath existed during activity and improved during rest. Her both feet were getting to swollen. There was no chest pain or cough. There was no history of hypertension and



diabetes mellitus (DM). She has an atrial septal defect (ASD) congenital heart disease, without routine medication, history of surgery, or a history of allergies/ asthma. Her last meal was around yesterday afternoon.

On the primary survey, the airway was clear but breathing and circulation show abnormalities. There was tachypnea (respiratory rate 32-36 per minute.), pulse oximetry showed 97-98%, retraction of intercostal space, and increased work of breathing. Oxygen therapy that was given was nasal cannula 3 liters per minute. The blood pressure was 130/90 mmHg, and heart rate tachycardia (122 beats per minute). The patients' disability was conscious and had a good orientation.

On physical examination, both conjunctiva was not anemic and sclera not icteric. There were bibasilar rhonchi. We found that heart sound was regular but with systolic ejection murmur sound over the area of the pulmonary valve at the second intercostal space. There were no gallop sound or chest wall retraction. Abdomen examination showed 37 weeks of gestation, and fetal heart rate was normal (132 beats per minute). The liver and spleen are not evident. The limb showed pretibial edema, but still warm and had good perfusion.

Laboratory test was within the normal range except for the leucocyte ($11.960 \times 10^9/L$), lactic acid dehydrogenase or LDH (307 U/L), and albumin level (2.6 d/dL). Electrocardiography before surgery resulted in sinus tachycardia. Echocardiography showed that the dimensions of the right ventricular and right atrium, were dilated, wall motion, systolic function, and diastolic function, and valve were normal. Left ventricle ejection fraction (LVEF) was 80%. There are ASD and PH, Obstetricians planned an emergency c-section, Internist's consultation result was ASD Functional NYHA IV with pulmonary edema. They advised to give intravenous furosemide 2-4 mg/hour continuously, and Dorner 20 mg every 12 hours orally. Our assessment was G₁P₀A₀ pregnant 39 weeks with Congestive Heart Failure (CHF) NYHA IV, pulmonary edema, ASD, PH, and hypoalbuminemia (ASA physical status IV E). After got the consent for the surgery and anesthetic procedure, the patient was admitted to the operating theatre. After preparing all the neuraxial anesthesia needs, we did the single-shot spinal anesthesia using isobaric bupivacaine combined with fentanyl as an adjuvant. The dose of bupivacaine isobaric was 7.5 mg (using concentration 0.5%) and fentanyl was 25 µcg. We injected the drugs at the L3-L4 and reached the blockage target as high as T6. After injection in a sitting position, the head of the bed was positioned as high as 30 degrees. Hemodynamic was stable intraoperatively (Figure 1). The operation lasted 1 hour 15 minutes,



with bleeding as much as 300 ml. A baby was born with a weight of 2250 grams, length of baby 46 cm, and Appearance, Pulse, Grimace, Activity, and Respiration (APGAR) score of 8/9. The patient was admitted to the intensive Care Unit (ICU) for one day and discharged from the hospital on the 5th day of hospital care.

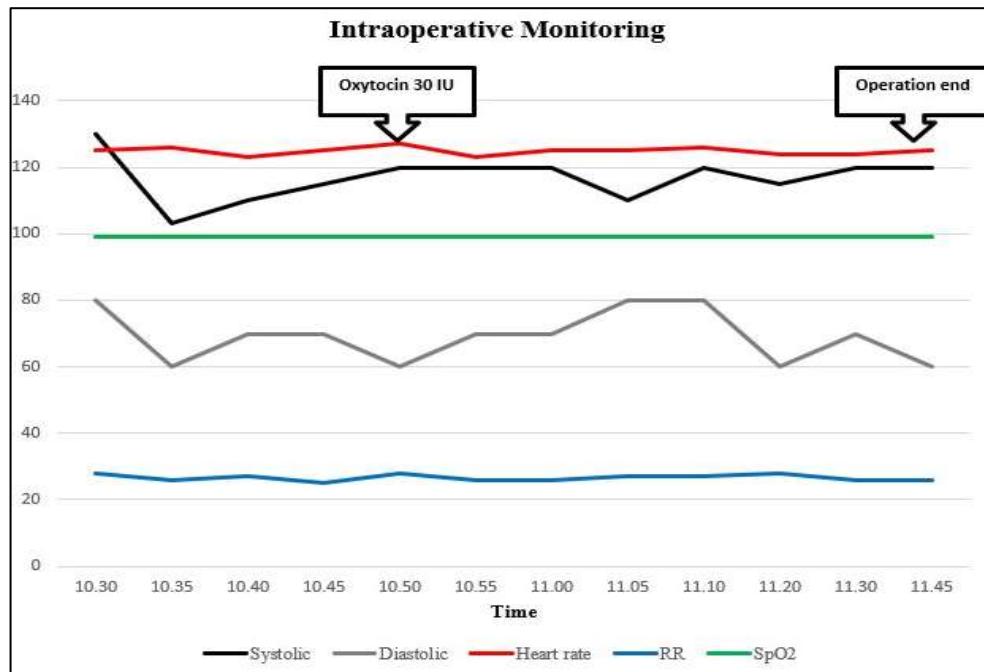


Figure 1. Hemodynamic monitoring

Discussion

A review issued by the European Society of Cardiology (ESC) showed that higher maternal mortality rates were found in patients with PH who received general anesthesia (GA). Patients who received general anesthesia were four times more likely to die, compared with patients who received regional anesthesia (RA). This could reflect a higher risk for the use of general anesthesia in patients with PH. GA is known to suppress cardiac contractility (volatile agents), increase pulmonary vascular resistance or PVR (positive pressure ventilation), and may result in increased pulmonary arterial pressure during laryngoscopy and intubation. General or epidural anesthesia must be performed by an experienced anesthesiologist during the beginning of labor to avoid an increase in cardiac output associated

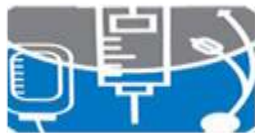

with contractions and pain. However, it is not possible to rule out the possible link between GA and maternal mortality derived from C-section or GA especially in high-risk patients.⁸

Whereas another study by Algert CS et al., with a cohort design study covering 50,806 samples of the comparison of the effects of RA with GA on neonates, concludes concerns about the effects of GA on neonates largely focusing on acid-base status, resuscitation and APGAR score at 1 minute. The rate of neonatal intubation increased after the use of GA in this study showed a dangerous level, and the persistence of a low 5-minute APGAR score indicates that adverse effects can last longer than after delivery. The relative risk for the occurrence of intubation and a low 5-minute APGAR score greatly decreases if the regional block is used for all three defined risk groups and at all hospital levels. The greatest absolute increase in intubation rates and a 5-minute APGAR score <7 for labor performed with GA occurred in the most vulnerable infants: those born CS were emergency due to fetal distress. Doctors considering the use of GA for labor with CS must be aware of the possible consequences of this for infants, for planned and emergency CS.⁹

In this case report the use of the spinal anesthesia technique with isobaric bupivacaine 0.5% 7.5 mg and fentanyl 25 µg; body position was raised 30 degrees after injection. Although hypotension due to decreased systemic vascular resistance which is a result of the blockade of preganglionic sympathetic fibers is still a problem with neuraxial blocks. This situation can endanger the mother and baby. Hypotension is associated with high spinal blockade. The higher the spinal blockade, the compensation mechanism due to sympathetic barriers is increasingly suppressed. The incidence of hypotension due to spinal anesthesia in C- section patients varies and is quite high.¹¹ Prevention of hypotension can be done in one way i.e. small doses of local anesthesia combined with opioid analgesics.¹⁴ Oxytocin administration can cause tachycardia and hypotension, but by intravenous administration can be well tolerated.⁵

The goal of anesthesia is to obtain adequate levels of blockade with a combination of low-dose spinal anesthesia plus fentanyl adjuvant, which does not significantly affect hemodynamics, with a low dose of local anesthesia can reduce side effects and the addition of adjuvants adds to the potentiation of analgesia.¹¹ The theme of low dose bupivacaine with adjuvant Fentanyl has a beneficial effect in line with a meta-analysis by Tang Qiu, M et al. about the combination of low-dose bupivacaine with opioids that provide good analgesia



accompanied by reduced incidence of intraoperative hypotension in C-section patients receiving spinal anesthesia, where high-dose bupivacaine (≥ 10 mg, HB), bupivacaine low dose (< 10 mg, LB) and a combination of low dose bupivacaine and opioids (LBO). The results of 11 randomized controlled trials including 605 mothers were analyzed. The results of this meta-analysis show that compared to the high-dose bupivacaine (HB) regimen, the low-dose bupivacaine (LB) regimen reduces the incidence of intraoperative hypotension with unsatisfactory analgesia. The combination regimen of low-dose bupivacaine and opioids (LBO) significantly reduces the incidence of intraoperative hypotension with the efficacy of reliable analgesia. So we conclude that compared to conventional HB regimens and LB regimens, LBO regimens not only reduce intraoperative hypotension but also provide reliable analgesia. Therefore, LBO regimens should be considered as a combination of drugs that are favored by spinal anesthesia in caesarean section.¹³

The spinal technique in patients undergoing C-section with PH was performed based on a case report by Yang JH et al. Reported planned cesarean delivery for PH patients to safely deliver a newborn baby by C-section under spinal anesthesia. Regional anesthesia to control pain and to avoid pain-related tachycardia is needed, but close observation is needed to avoid sudden hypotension and decreased cardiac output due to maternal systemic vasodilation. Literature review by Weiss et al. and Bedard et al., on the other hand, showed a neonatal survival rate of almost 90% regardless of the pulmonary hypertension subgroup, with stunted fetal growth reported in 3% to 33% of pregnancies. In this case, the newborn APGAR score gets a good score and physical examination results.¹⁰

Elevating the body is expected in addition to the comfort of patients with pulmonary edema also has an influence on anesthetic techniques. Where previous studies have compared the differences in height of sensory blockade of spinal anesthesia conducted in a sitting and lateral position for C-section using a combination of bupivacaine with different linearity (hyperbaric, isobaric, or hypobaric) and diamorphine. The difference in local anesthetic toxicity does not affect the height of sensory blockade when spinal anesthesia is performed in the lateral position, but it produces a significant difference when spinal anesthesia is carried out in a sitting position. Hyperbaric local anesthetics move in the direction of gravity, isobaric is not influenced by gravity, while hypobaric is against gravity so it is found that the spread of hypobaric local anesthetics is higher than that of isobaric and hyperbaric.¹⁵ Kolarkar P et



al's study, found that the Sitting Group has a lower sensory block height than the Group lying down; also need less ephedrine. The duration of postoperative analgesia was extended in both fentanyl groups. The long sitting position after spinal anesthesia not only limits the spread of local anesthetic, results in lower sensory block heights but also reduces the incidence of hypotension and the need for intraoperative ephedrine in cesarean delivery.¹⁶ This is in line with the study of Lee MH et al, where head elevation during CSE in CSE at C-section is better than positioning without head elevation from lateral to supine, because it is associated with a more gradual onset, suitable block height, and better hemodynamic parameters.¹⁷

Conclusion

Single-shot spinal anesthesia with small doses of bupivacaine and adjuvant can be used as an alternative technique in emergency c-section for patients with congestive heart failure due to congenital atrial septal defect, and pulmonary hypertension. However, we have to put concern about the possibility of the side effects like high-spinal anesthesia, hypotension, and others. Beside the technique itself, perioperative evaluation using multidisciplinary approach can improve patient's outcome.

References

1. Frolich MA (2013). Morgan & Mikhail's clinical anesthesiology. In: Butterworth JF, Mackey DC, Wasnick JD (eds). Maternal & fetal physiology & anesthesia, New York, McGraw-Hill, p 825-841.
2. Chandrasekhar S, Tolpin DA, Mangano DT (2013). Shnider and Levinson's anesthesia for obstetrics fifth edition. In: Suresh MS, Segal S, Preston RL, Fernando R, Mason CL (eds). Anesthetic management of the pregnant cardiac patient. USA, Lippincott Williams & Wilkins, 30, p 484-523.
3. Vidovich MI (2014). Chesnut's obstetric anesthesia principles and practice fifth edition. In: Chestnut DH, Wong CA, Tsen LC, et al (eds). Cardiovascular disease. USA, Elsevier Saunders, p 960-1030.
4. Weiner MW, Hamburger J, Beilin Y (2017). Kaplan cardiac anesthesia for cardiac and non cardiac surgery seventh edition. In: Kaplan JA, Augoustides JGT, Jr, GRM, Maus, T,



- Reich DL (eds). The pregnant patient with cardiac disease, USA, Elsevier Saunder, p 1582- 1600.
5. Prijambodo GD, Rahardjo E (2013). Anestesi obstetri. In: Bisri T, Wahjoeningsih S, Suwondo BS. Seksio sesarea pada penyakit katup jantung, Bandung, SAGA-Kolegium Pendidikan KAO Kolegium Anesthesiologi dan Terapi Intensif Indonesia (KATI), p 119.
 6. Boom CE, Adriane P, Cintyandy R (2013). Panduan klinis perioperatif kardiovaskular anestesia. Jakarta, KATI-Aksara Bermakna, p 225.
 7. Cannesson M, Earing MG, Collange V, et al (2009). Anesthesia for noncardiac surgery in adults with congenital heart disease. *Anesthesiology* 111, 432-40.
 8. Be´dard E, Dimopoulos K, Gatzoulis MA (2009). Has there been any progress made on pregnancy outcomes among women with pulmonary arterial hypertension?. *Eur Heart J* 30, 256–265.
 9. Algert CS, Bowen JR, Giles WB et al (2009). Regional block versus general anaesthesia for caesarean section and neonatal outcomes: a population-based study. *BMC Med* 7, 20.
 10. Yang JH, Kim JY, Lee DH et al (2013). A successful delivery of a woman with pulmonary arterial hypertension: Under close observation and without medication. *J Korean Society Hypertension* 19, 90-97.
 11. Siahaan A, Solihat Y (2014). Anestesi spinal pada seksio sesaria wanita dengan tetralogy fallot tidak terkoreksi. *Jurnal Anesthesiologi Indonesia* 6, 208-213.
 12. Senapathi TGA, Budiarta IG, Astuti MK (2018). Low dose spinal anaesthesia for cesarean section in gravida with rheumatic heart disease. *Bali Journal of Anesthesiology* 2, 25-28
 13. Qiu MT, Lin FQ, Fu SK, et al (2012). Combination of low-dose bupivacaine and opioids provides satisfactory analgesia with less intraoperative hypotension for spinal anesthesia in cesarean section. *CNS Neuroscience & Therapeutics* 18, 426–432.