

53. MKS Madu, 2020 Turnitin

by Irfannuddin Irfannuddin

Submission date: 13-Nov-2021 10:38AM (UTC+0700)

Submission ID: 1701384999

File name: 53._MKS,_Madu,_2020.pdf (4.12M)

Word count: 3714

Character count: 18772

COMPARISON OF HONEY EFFECTIVENESS WITH SILVER SULFADIAZINE 1% ON THE FORMATION OF EPITHELIAL POST DEEP DERMAL BURNS INJURY AT RATS

Chandra Bobby Hadinata¹, Abda Arif², Irfannuddin³

¹Surgical Resident, ²Sub Division of Plastic Surgery, Faculty of Medicine, Universitas Sriwijaya/Mohammad Hoesin Hospital, ³Division of Physiology and Medical Physics, Faculty of Medicine, Universitas Sriwijaya

Email: abda.arif@yahoo.com

ABSTRACT

This study is an experimental animal study that assesses the difference in effectiveness of healing deep dermal burns using 1% honey and silver sulfadiazine. The subjects of this study were rats that had deep dermal burns on their backs which were then treated with 1% honey and silver sulfadiazine. Then the epithelialization thickness was measured using a microscope. In this study, the results showed that in the honey administration group epithelium occurred with an average of 1.111 ± 0.298 or 49.42%, whereas in the silver sulfadiazine 1% cream group epithelium had occurred with an average of $1,100 \pm 0.336$ or 50.57%. There was no statistically significant difference between honey epithelium with silver sulfadiazine cream 1% on the 4th day with a value of $p = 0.921$. In the Honey giving group epithelium occurred with a mean of 1.496 ± 0.225 , meaning that the epithelium increased by $20.92 \pm 5.57\%$. In the group giving 1% silver sulfadiazine cream epithelium occurred on the 14th day with a mean of 1.362 ± 0.166 , meaning that the epithelial increase was $16.12 \pm 10.42\%$. There were no statistically significant differences on the 7th day epithelium with a value of $p = 0.171$. Comparison of 10th day Epithelial Thickness between Honey Giving Group and SSD cream 1%, In the Honey group, epithelium occurred with an average of 1.746 ± 0.314 , meaning that the epithelium increased by $12.12 \pm 2.02\%$, whereas in the silver sulfadiazine 1% group, epithelium occurred with an average of 1.758 ± 0.244 , meaning that the epithelium increased by $12.12 \pm 0.89\%$. There was no statistically significant difference in epithelium on the 10th day with a value of $p = 0.926$. Honey and Silver 1% sulfadiazine cream have the same effectiveness against epithelial formation in deep dermal burns. Giving honey can be recommended as a treatment for deep dermal burns because it has the effectiveness of epithelial formation in deep dermal burns. Further research needs to be done on the higher degree of burns as well as research on the side effects that may be caused during honey administration. Further studies standardize the composition and effective dose of honey for the treatment of burns so that it is used by the standard treatment standards for burns.

Keywords: Honey, Silver Sulfadiazine 1%, Epithelial Formation, Deep Dermal Burns

28

1. INTRODUCTION

Burns are damage to the skin and / or without the underlying tissues which can be caused by fire, hot water, electricity, radiation, and blast injuries. Burns are a type of trauma with high morbidity and mortality

rates, so they require special management from the start. Complications of burn cases include shock, infection, inhalation trauma, systemic inflammatory response syndrome (SIRS) and multiple organ damage.

Infection in burns is a major cause of sepsis. The main purpose of treating burns in general is rapid healing by returning optimal function and maintaining good aesthetic results. This can be achieved by preventing further infection by providing an optimal atmosphere for healing the wound.¹

Burns are one of the injuries that often occur in society and have become a global problem. Based on data from the World Health Organization (WHO) in 2004, almost 11 million people worldwide suffered severe burns that required medical treatment.² According to the American Burn Association (ABA), Between 2011 and 2015, around 486,000 burns were seen in the Emergency Department. In 2016, around 3,390 civilian deaths were due to fires, which included 2,800 deaths due to residential structure fires, 150 deaths due to non-residential fires, 355 from vehicle fires, and 85 from other fires.³ The prevalence of burns in Indonesia in 2013 was 0.7% and decreased by 1.5% compared to 2008 of 2.2% (MOH, 2013).⁴ The death rate due to burns in Indonesia is around 195,000 deaths per year.⁵ Burns become a global problem and are important because the effects of morbidity and complications caused by burns are very serious.

Problems that often arise in burn patients are complications and the wound healing process that lasts very long. The process of healing burns as wounds in general includes three phases, namely the inflammatory phase is characterized by vasodilation, fluid extravasation and edema, the proliferation phase is characterized by revascularization and wound closure with the production of keratinocytes and the remodeling phase which is characterized by wound maturation through the formation of collagen and elastin by cells - Fibroblast cells.⁶

The use of honey as a drug has been known for tens of thousands of years ago

and is used as a treatment for stomach, cough, and eye diseases.⁷ In addition, honey can also be used as a topical therapy for burns, infections, and ulcer wounds. Until now there have been many research results that report that honey is effective for wound care. There are several studies that report that honey is very effective as a topical therapy for wounds, which results in a significant increase in granulation and collagen tissue and a period of epithelialization significantly.^{8,9}

Honey has a high sugar content so that high osmolarity has a strong interaction with water molecules causing the shrinkage of the bacterial wall will be able to inhibit the growth of microorganisms. Honey with a low pH (3.6-3.7) can provide an acidic environment to the wound so that it can prevent bacteria from penetrating and colonizing.⁸ Honey also contains H₂O₂ (Hydrogen Peroxide) which produces the reaction of the glucose oxidase enzyme so that it has antibacterial properties.¹⁰

Honey also functions as an antioxidant due to the presence of vitamin C which is contained in honey. Aljadi A M, et al., (2004) reported that honey has antioxidants mainly because of flavonoids and phenolics so it is responsible for free radicals involved in various aspects of inflammation.

The use of silver sulfadiazine 1% cream in the treatment of burns is important to prevent infection. This cream consists of 2 components of an active ingredient namely silver / Ag (Ag) which acts as a bactericidal, and sulfadiazine (Sulfonamide) acts as a bacteriostatic, so that the combination of silver and Sulfadiazine has a broad spectrum of gram-positive and gram-negative bacteria.¹⁰

Prevention of infection can accelerate granulation tissue formation process. Formation of granulation tissue is an important stage in the proliferation and wound healing phase.¹¹ The purpose of this

study was to determine the differences in the effectiveness of the use of honey with silver sulfadiazine 1% on epithelial formation in deep dermal burns.¹¹

2. METHOD

² This research is an experimental study using a posttest only control group design study design, where measurements are made after the treatment is finished. This research was conducted at the Animal House Faculty of Medicine Sriwijaya University, Palembang for maintenance and treatment of white rats (*Rattus norvegicus*) and Pathology Laboratory of RSUP Dr. Mohammad Hoesin Palembang for skin examination of white rats (*Rattus norvegicus*). In this study the number of treatment groups was (t = 2) with each group as many as (n = 16) so that the number of samples obtained in this study was 32. Group I (Mice that are smeared with honey): as many as 16 individuals Group II (Mice that are smeared with silver sulfadiazine 1%): as many as 16 individuals Inclusion criteria of this study: (a) White rat (*Rattus norvegicus*) male. (b) Average age of 2-3 months. (c) Weight \pm 200-300 grams. (d) Rats in good health, activity, and normal behavior.

Samples removed from this study were experimental rats that died after treatment to make burns. After the back of the rat was shaved and given anesthesia with ketamine 50 mg / kgBW IM.¹¹ Manufacture of thermal burns using a metal plate weighing 42,48 grams (figure 3.1) with a diameter of 1 cm at a temperature of 100°C that has been heated with boiling water for 5 minutes. then the back of the mouse was affixed to a metal plate for 15 seconds at a pressure corresponding to the weight of the metal against gravity. Burns made 3 wounds on the back of rats for sampling on days 4, 7 and 10 as shown in figure 3.2(A).¹²

After the rats were given burns, the wounds were cleaned with Normal saline. Furthermore, the rats were treated according to the treatment group. Group 1 was smeared with honey with 0.5 gram once a day, group 2 was smeared with Silver Sulfadiazine 1% 0.5 gram once a day for days 4, 7 and 10. The smeared area was then covered with transparent film then covered with gauze and glued together with elastomol. During the treatment the rats were fed mixed with paracetamol to reduce pain in mice, paracetamol was given 3 times per day.



Figure 3.1. aluminum metal plates for making burns on the backs of mice

The treated white rat was treated with ketamine at a dose of 50 mg / kg IM. Then take 0.5 cm x 1 cm leather preparations (figure 3.2(B)). Skin samples are taken on days 4, 7 and 10, then the wound is sewn. The cut skin is fixed with a 10% BNF (Neutral Formaler buffer) solution. Then the sample is sent to the Anatomical Pathology Laboratory for the preparation of preparations with HE (Hematoxylin Eosin) staining.

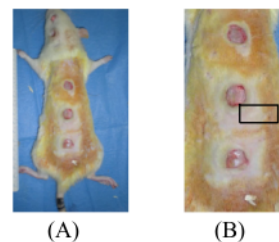


Figure 3.2:¹⁸ A. Example of making burns on a mouse's back. B. Examples of burn sample collection.

Measurement of the epithelialization thickness of skin tissue preparations in vertical cuts is measured starting from the edge of the wound bed to the dermis where the proliferation ends with a 40x magnification microscope equipped with microrulers in μm units. Analysis of research data using a computerized system with a significance level of $p < 0.05$. Statistical analysis was performed by testing two different numerical data to determine the thickness of the epithelium and wound edge distance in the administration of honey and Silver Sulfadiazine 1%, on days 4, 7 and 10.

3. RESULT

Comparative clinical trial research has been conducted which aims to determine the difference in effectiveness of honey with silver sulfadiazine 1% cream in the treatment of deep dermal burns starting in February 2020. Research was conducted on white rats with a sample of 32 subjects. Subjects were divided into 2 groups, namely the Honey group and the 1% silver sulfadiazine cream group (SSD 1%), each of

which consisted of 16 subjects. The results of homogeneity characteristics test which included body weight of rats to meet the requirements of experimental research. Homogeneity test results of rat body weight in both the honey treatment group and 1% SSD obtained p value of 0.391 ($p > \alpha$) meaning that the body weight of rats in the two groups was not significantly different (homogeneous).

Difference in epithelial thickness between day 4, day 7 and day 10 of the Honey Group

The difference in epithelial thickness between day 4, day 7 and day 10 in the honey group was analyzed using paired t test. The results of the analysis of the mean difference in epithelial thickness between days 4 to 10 have increased epithelial thickness. Statistical tests show significantly different results (p value = 0,000) epithelial thickness between days 4 and 7, as well as differences in days 4 and days 7 (p value = 0,000), days 7 and days 10 (p value = 0,000) showed significantly different results ($p < \alpha$). The complete analysis results are presented in the table below:

Table 1. Differences in epithelial thickness between day 4, day 7 and day 10 of the Honey Group

Time Measurement	n	Epithelial Thickness Mean \pm SD	Differences	p value
Day 4 Day 7	16 16	1,111 \pm 0,298 1,496 \pm 0,225	0,385	0,000
Day 4 Day 10	16 16	1,111 \pm 0,298 1,745 \pm 0,314	0,634	0,000
Day 7 Day 10	16 16	1,496 \pm 0,225 1,745 \pm 0,314	0,249	0,000

*Uji paired t test

Rat skin samples with HE (Hematoxylin Eosin) staining were seen under a microscope

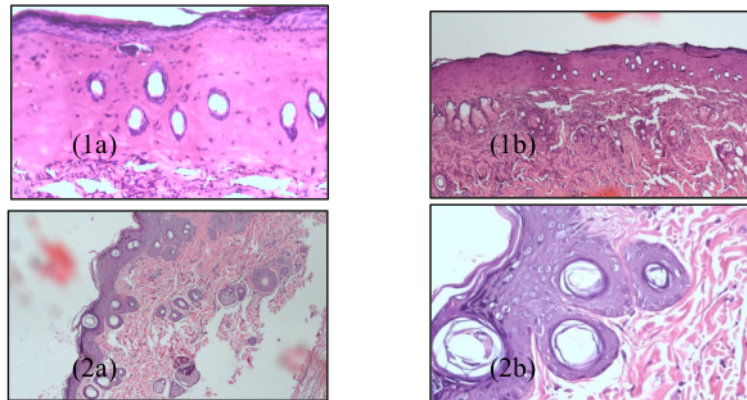


Figure 1. Honey Group day 4 (1a and 1b) and SSD group 1% (2a and 2b)

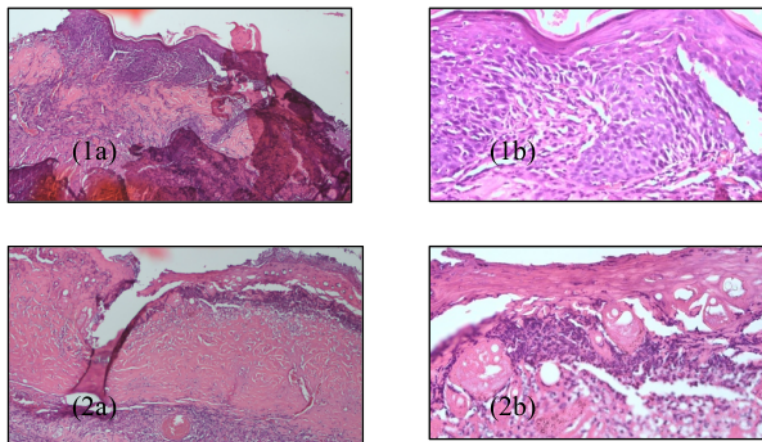


Figure 2. Honey Group day 7 (1a and 1b) and SSD group 1% (2a and 2b)

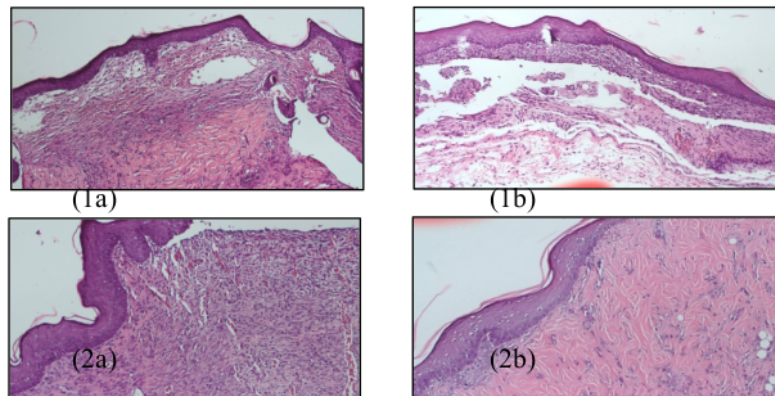


Figure 2. Honey Group day 10 (1a and 1b) and SSD group 1% (2a and 2b)

Difference in epithelial thickness between day 4, day 7 and day 10 SSD group 1%

Differences in epithelial thickness between day 4, day 7 and day 10 in the SSD 1% group were analyzed using the Wilcoxon test. The results of the analysis of the mean difference in epithelial thickness between days 4 to 10 have increased epithelial thickness. Statistical tests show significantly different

results (p value = 0,000) epithelial thickness between days 4 and 7, as well as differences in days 4 and days 7 (p value = 0,000), days 7 and days 10 (p value = 0,000) showed significantly different results (p < α). The complete analysis results are presented in the table below:

Table 2 Differences in epithelial thickness between day 4, day 7 and day 10 SSD group 1%

Time Measurement	n	Epithelial Thickness Mean±SD	Differences	p value
Day 4	16	1,100± 0,336	0,262	0,000
Day 7	16	1,362 ± 0,165		
Day 4	16	1,100± 0,336	0,658	0,000
Day 10	16	1,758 ± 0,243		
Day 7	16	1,362 ± 0,165	0,396	0,000
Day 10	16	1,758 ± 0,243		

*Uji wilcoxon

Comparison of the thickness of the 4th, 7th and 10th day of the Epitalization of Honey and SSD cream 1%

Data on rat skin examination results were analyzed using the SPSS program and Independent T Test. The results showed that epithelial day 4 (p = 0.921), while the epithelium on the 7th day (p = 0.171) and the 10th day (p = 0.926) using the parametric test that was Mann Whitney Test. In a descriptive manner, in the group given MAD, the majority of them had a retail thickness that was more than 1% silver sulfadiazine cream.

In this study, the results showed that in the honey administration group epithelium occurred with an average of 1.111±0.298 or 49.42%, whereas in the silver sulfadiazine 1% cream group epithelium had occurred with an average of 1,100 ±0.336 or 50.57%. Based on the Independent T Test analysis, there was no statistically significant

difference between honey epithelium with silver sulfadiazine cream 1% on the 4th day with a value of p = 0.921.

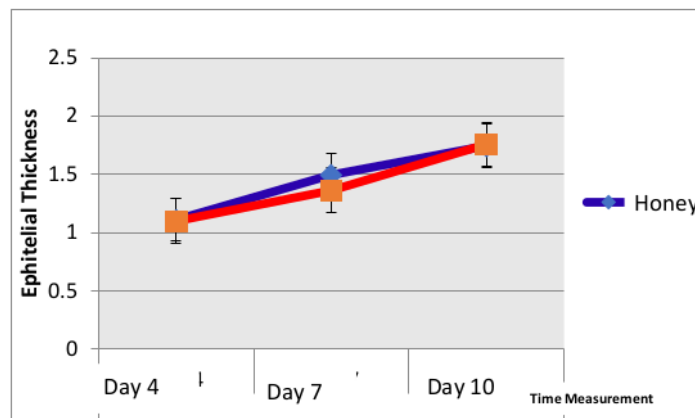
In the Honey giving group epithelium occurred with a mean of 1.496±0.225, meaning that the epithelium increased by 20.92 ± 5.57%. In the group giving 1% silver sulfadiazine cream epithelium occurred on the 7th day with a mean of 1.362±0.166, meaning that the epithelial increase was 16.12 ± 10.42%. Based on the analysis of the Mann Whitney Test, there were no statistically significant differences on the 7th day epithelium with a value of p = 0.171.

Comparison of 10th day Epithelial Thickness between Honey Giving Group and SSD cream 1%. In the Honey group, epithelium

occurred with an average of 1.746 ± 0.314 , meaning that the epithelium increased by $12.12 \pm 2.02\%$, whereas in the silver sulfadiazine 1% group, epithelium occurred with an average of 1.758 ± 0.244 , meaning

that the epithelium increased by $12.1225 \pm 0.89\%$. Based on the Independent T Test analysis, there was no statistically significant difference in epithelium on the 10th day with a value of $p = 0.926$.

Figure 4. Comparison of 4th to 10th day epithelium in both groups



4. DISCUSSION

This study is a comparative clinical trial that aims to determine the difference in effectiveness of honey administration with 1% silver sulfadiazine cream in the treatment of deep dermal burns. In this study 32 subjects were divided into 2 groups: the honey giving group and the Silver Sulfadiazine 1% cream group, each with 16 subjects. From the statistical average rate of epithelialization in deep dermal burns between honey with silver sulfadiazine did not have a significant difference. Both samples gave equally good results on epithelial formation in deep dermal burns.

The results of research conducted by Angga Nugraha et al. Showed the results that honey with silver sulfadiazine did not have a significant difference in the healing of burns because both preparations have

active substances as anti-infective agents.¹³ Honey content such as acidic pH can prevent bacteria from penetrating and colonizing and hyperosmolarity which can inhibit the growth of microorganisms, anti-inflammatory effect by reducing lymphatic fluid from wound tissue thereby accelerating edema and exudate.¹⁴ The content of the glucose oxidase enzyme in honey when dissolved with liquid (exudate) will react to produce hydrogen peroxide has antibacterial properties and chemical debridement effect of dead tissue.¹⁵

Silver Sulfadiazine 1% contains silver / silver (Ag) which acts as bacteriocide, and sulfadiazine (Sulfonamide) acts as bacterostatic, so as to prevent microbial infections in burns so that inflammation becomes controlled. The cream content of Silver Sulfadiazine 1% can moisturize burns so that this condition supports the formation of granulation tissue.¹⁶

The inflammatory phase is an important stage in wound healing. This phase is homeostatic, removes dead tissue, prevents colonization and infection of pathogenic bacteria. Various inflammatory mediators namely prostaglandins, interleukin I (IL-I), Transforming growth factor (TGF), and bacterial degradation products such as lipopolysaccharide. Lipopolysaccharides will attract neutrophils so that they will filter the fibrin matrix and fill the wound cavity. Macrophages follow neutrophils to the wound after 48-72 hours which play a role in eliminating bacteria by producing and releasing proteination and reactive oxygen species (ROS).¹⁷

Infection in burns that are not optimally treated will induce re-triggering the emergence of various inflammatory mediators so that there is an extension of the inflammatory phase and slow to enter the proliferation phase. Honey and Silver Sulfadiazine 1% cream are topical agents that are effective in preventing microbial infections and anti-inflammatory in burns. Silver Sulfadiazine 1% cream other than as an antibacterial in burns can occur complications in the form of allergic reactions, and methoglobinemia.²⁹ Honey is a natural substance that is not irritant, non-toxic, easy to obtain, economical, and easy to use. No literature has yet been found to conduct research on the side effects of honey as a topical therapy in burns.

5. CONCLUSION

Honey and Silver 1% sulfadiazine Cream have the same effectiveness against epithelial formation in deep dermal burns. Giving honey can be recommended as a treatment for deep dermal burns because it has the effectiveness of epithelial formation in deep dermal burns. Further research needs to be done on the higher degree of burns as

well as research on the side effects that may be caused during honey administration. Further studies standardize the composition and effective dose of honey for the treatment of burns so that it is used by the standard treatment standards for burns.

REFERENCES

- [1]. The Australian and New Zealand Burn Association Limited. Emergency Management of Severe Burn (ESMB): Course Manual 8th edition. 2013. The Education of The Australian and New Zealand Burn association Limited.
- [2]. World Health Organization. Median center : Burn 2018
- [3]. American burn association. National burn awareness week. 2018
- [4]. Aditya Wardana et al. 2017. The epidemiologi of burn in indonesian's national referral burn center from 2013 to 2015. *Burn open* 1 67-73.
- [5]. Departemen Kesehatan RI (2013). *Riset Kesehatan Dasar 2013, Laporan Nasional 2013*, pp. 1-384. doi: 1 Desember 2013. 6
- [6]. Smeltzer, et al, 2002, *Buku Ajar Keperawatan Medikal Bedah Brunner dan Suddarth* (Ed.8, Vol. 1,2), Alih bahasa oleh Agung Waluyo...(dkk), EGC, Jakarta. 19
- [7]. Brunicardi F C, et al. 2005. *Schwartz's Principles of surgery*. 8 edition. New York: McGraw-Hill 16 Medical Publishing
- [8]. Moenadjat Y. *Luka Bakar: Masalah dan Tatalaksana*. Edisi ke-4. Jakarta: 23 Iai Penerbit FKUI. 2009.
- [9]. Charles H. Thorne. *Grabb and Smith* 7 Plastic Surgery 6th edition. 2007. Associate Professor of Plastic Surgery NYU Medical Center New York, New York.

- [10]. Broughton II, G et al .2006. Wound healing: an overview. Plastic Reconstruction Surgery 117 (Supplement) : 1eS-32eS
- [11]. Li, J., Chen, J., Kirsner, R. 2007. Pathophysiology of acute wound healing. Clinics in Dermatology. Vol: 25.
- [12]. Danielle Santos Tavares Pereiraetal. 2012. Development of Animal Model for Studying Deep Second-Degree Thermal Burns. Journal of Biomedicine and Biotechnology Volume 24:12
- [13]. Angga Nugraha et al. Perbandingan Tingkat Kesembuhan Luka Bakar Derajat II antara Pemberian Madu Topikal Nektar Kopi dengan Silver Sulfadiazine pada Tikus Putih (*Rattus norvegicus*) Jantan Galur Sprague Dawley. Medical Journal of Lampung University
- [14]. Gupta. Theurapeutic efficacy of honey in infected wound. Indian journal of animal sciences. 1992 ; 62 (12) : 521-3
- [15]. Efem SEE, 1998. Clinical observation on the wound healing properties of honey. Br J. Surg., 75:670-681.
- [16]. Widagdo TD. Perbandingan pemakaian aleo vera 25%, 40% dan silver sulfadiazine 1% topikal pada penyembuhan luka bakar derajat II. Disertasi doktoral, program pasca sarjana universitas diponegoro. 2004.
- [17]. Gurtner GC, 2007. Woung healing, normal and abnormal: grabb and smith's plastic surgery 6th edition, p: 15-22.
- [18]. yan-teng kho. Wound contraction effects and antibacterial properties of Tualang honey on full-thickness burn wounds in rats in comparison to hydrofibre. BMC Complementary and Alternative Medicine 2010, 10:48

53. MKS Madu, 2020 Turnitin

ORIGINALITY REPORT

13%

SIMILARITY INDEX

11%

INTERNET SOURCES

8%

PUBLICATIONS

6%

STUDENT PAPERS

PRIMARY SOURCES

1	lufb.llu.lv Internet Source	1%
2	ejournal.unsri.ac.id Internet Source	1%
3	link.springer.com Internet Source	1%
4	digilib.unila.ac.id Internet Source	1%
5	bestdefense.com Internet Source	1%
6	ukh.ac.id Internet Source	1%
7	idoc.pub Internet Source	1%
8	www.nzma.org.nz Internet Source	1%
9	Submitted to Universiti Selangor Student Paper	1%

10	eprints.undip.ac.id Internet Source	<1 %
11	repository.unair.ac.id Internet Source	<1 %
12	saldyusuf.blogspot.com Internet Source	<1 %
13	adoc.pub Internet Source	<1 %
14	pdfs.semanticscholar.org Internet Source	<1 %
15	bmccomplementmedtherapies.biomedcentral.com Internet Source	<1 %
16	www.scribd.com Internet Source	<1 %
17	Azmeilia Syafitri Lubis, H.R. Yusa Herwanto, Andrina Y.M. Rambe, Delfitri Munir, Harry A. Asroel, Taufik Ashar, Aznan Lelo. "The effect of honey on post-tonsillectomy pain relief: a randomized clinical trial", Brazilian Journal of Otorhinolaryngology, 2021 Publication	<1 %
18	Satoko Narita, Masashi Nomura, Daisuke Kageyama. "Naturally occurring single and double infection with Wolbachia strains in the butterfly Eurema hecabe: transmission	<1 %

efficiencies and population density dynamics
of each Wolbachia strain", FEMS Microbiology
Ecology, 2007

Publication

19

scholar.unand.ac.id

Internet Source

<1 %

20

Submitted to Cardiff University

Student Paper

<1 %

21

bmcpneumology.biomedcentral.com

Internet Source

<1 %

22

aac.asm.org

Internet Source

<1 %

23

library.skh.org.tw

Internet Source

<1 %

24

www.hindawi.com

Internet Source

<1 %

25

Gerald M. McGuire, Peitan Liu, Hartmut
Jaeschke. "Neutrophil-induced lung damage
after hepatic ischemia and endotoxemia",
Free Radical Biology and Medicine, 1996

Publication

<1 %

26

A Aditiawardana, Fauzia Liani, Chandra
Irwanadi, Nunuk Mardiana, P Pranawa. "Effect
of Calcineurin Inhibitor on Blood Glucose
Level in Non-Diabetic Kidney Transplant

<1 %

Patients", Indonesian Journal of Kidney and Hypertension, 2018

Publication

27

Opel Berlin, Liniyanti D Oswari, Susilawati Susilawati. "Comparison of Blood Pressure and Blood Glucose Levels in Chronic Kidney Failure Patients Before and After Hemodialysis Treatment in RSMH Palembang", Majalah Kedokteran Sriwijaya, 2019

Publication

<1 %

28

"Burns, Infections and Wound Management", Springer Science and Business Media LLC, 2020

Publication

<1 %

29

Amir Abbas Barzegari, Masood Hashemzaei, Raheleh Majdani, Ali-Reza Alihemmati. "Effects of topical treatment of second-degree burn wounds with Lactobacillus acidophilus on the wound healing process in male rats", Pharmaceutical and Biomedical Research, 2017

Publication

<1 %

30

Septi Dwi Rahmawati, Atik Setiawan Wahyuningsih, Eva Agustina Yalastyarini. "Diet Compliance Analysis Towards Blood Sugar Levels For Diabetes Mellitus Patients", Journal Of Nursing Practice, 2018

Publication

<1 %

Exclude quotes On
Exclude bibliography Off

Exclude matches Off