

Short Communication: Damage to the Histological Structure of Mice Liver (*Mus musculus*) Due to Excessive Consumption of Sodium Chloride

Rizqi Nur Ardiansyah^{1*}, Arum Setiawan², Yuanita Windusari³

¹ Department of Conservation Biology Program, Faculty of Science, Sriwijaya University, Jalan Padang Selasa 524, Palembang, South Sumatra 30139, Indonesia.

² Department of Biology, Faculty of Mathematics & Natural Sciences, Sriwijaya University, Jalan Raya Palembang-Prabumulih km 32, Indralaya, Indonesia.

*Corresponding author

E-mail address: rizqinurardiansyah@gmail.com (Rizqi Nur Ardiansyah).

Peer review under responsibility of Biology Department Sriwijaya University

Abstract

Salt or sodium chloride (NaCl) is used in everyday life mainly to give food taste. Salt is hepatotoxic, so excessive use of salt has an impact on the liver. The liver is one part of the organ that has an important role in the body's metabolism, especially in neutralizing toxins. The liver is composed of hepatocytes. There are 60% hepatocytes of the total cells in the liver. Hepatocytes are the main cells responsible for the central role of the liver in metabolism. Liver function becomes very vulnerable to damage because it continuously neutralizes toxins. Such damage can occur and affect the structure and function of the liver. This study was conducted to determine the structural abnormalities of hepatocytes that occur in the liver of mice (*Mus musculus*) due to excessive salt consumption. The method used in this study was a CRD (completely randomized design) method consisting of 1 control group and 3 treatment groups by sodium chloride (NaCl) with 6 replications. The parameter in this study was the level of hepatocyte damage in the liver of mice (*Mus musculus*). Hepatocyte damage that occurred was observed through histological preparations with Hematoxylin Eosin (HE) staining. The results of this study indicate that hepatocyte cell damage in the liver of mice (*Mus musculus*) increases due to continuous administration of excess sodium chloride (NaCl).

Keywords : Liver cells, Mice (*Mus musculus*), Sodium Chloride (NaCl)

Received: June 28, 2021, Accepted: February 2, 2022

1. Introduction

Salt or sodium chloride (NaCl) is a white solid in the form of crystals which is a collection of compounds with the largest proportion of sodium chloride (> 80%) and other compounds such as magnesium chloride, magnesium sulfate, calcium chloride and others. The characteristics of salt are easy to absorb water, with a density of 0.8-0.9 and a melting point at a temperature level of 801 Celsius [5]. Salt is commonly used as an additive in food, preservation processes, and food fermentation. Sodium chloride is useful for limiting the growth of spoilage organisms

and preventing the growth of organisms. However, certain bacteria can still grow in solutions with high salt content [3]. The sodium content in salt is quite dangerous so that the government set the dose for the use of salt in 2009, which was 5gr/day or equivalent to 1 teaspoon/day [8].

Salt is a food additive that is often used for flavoring in food and is important for human life, whether it is used as an additive to food or as a food preservative. Consumption of salt should not be excessive because salt contains sodium which works to hold water in the body, so that the circulating blood volume will increase. An increase in blood volume will increase the pressure experienced by the walls of

blood vessels called hypertension so that it can have a wide effect on health, such as heart problems, and stroke. Substances from food or drinks that enter the body are then digested by the digestive organs and then detoxified in the liver as the first organ to filter substances that enter the body.

The liver as a detoxifier of toxins works by breaking down toxic compounds into several compounds such as urea, ammonia, and uric acid [4]. The liver is a vital organ that has an important role in metabolism through several enzyme systems involved in biochemical transformations. The main cells that make up the liver are hepatocytes. Hepatocytes are the main cells responsible for the central role of the liver in metabolism. In the liver, hepatocytes are 60% of the total cells in the liver [1]. The liver is the organ responsible for neutralizing toxins. Therefore, this study was conducted to examine the effect of excess sodium chloride (NaCl) consumption on the liver cells of mice (*Mus musculus*).

2. Materials and Methods

This study used a completely randomized design method with 5 replications. Consisting of 1 control and 3 treatments with sodium chloride. Each treatment group was given a different dose, treatment 1: 269 mg, treatment 2: 520 mg, treatment 3: 780 mg, and control without NaCl induction. The mice (*Mus musculus*) used were 21 days old male mice. The staining method used in this study was hematoxylin eosin staining. Damage to cells was calculated using a microscope, the results were processed using the one-way ANOVA test and Duncan's follow-up test.

3. Results and Discussion

Liver Cell Damage

In the research that has been done, it is known that the average number of damaged liver cells has increased.

Table 1. shows differences in liver cell damage, the lowest damage occurred in the control, and the highest damage occurred in treatment 3. Table 4.1 shows an increase in the average number of damaged cells.

This is due to NaCl which affects the damage

to the liver. Based on these data, a one-way ANOVA test was carried out. ANOVA results ANOVA test results with a level of 0.01. that Sig. 001, <a = .01, which indicates the data is real.

Table 1. The Average number of damaged cells

No	Treatment	Average cell/ μm^2	Sig.
1	control	940.262 \pm	.001
2	P1	1443.047 \pm	
3	P2	1712.95 \pm	
4	P3	2015.057 \pm	

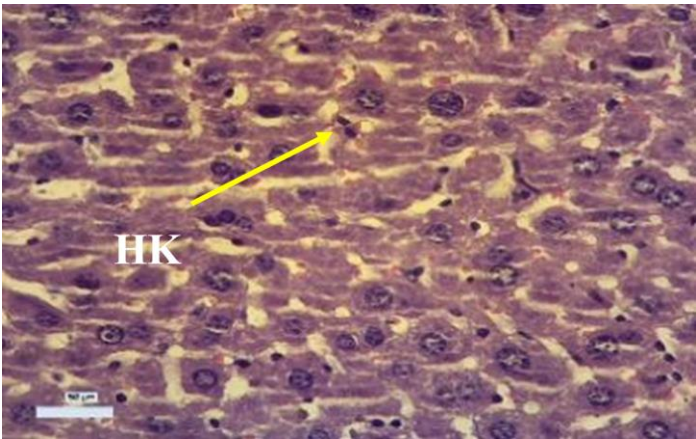


Figure 1. Hepatocyte cells undergo karyorexia. (HK: kariorexic hepatocytes)

Figure 1 shows the damage that occurs to hepatocyte cells due to excessive administration of sodium chloride (NaCl). This damage occurs due to the disruption of the enzyme catalase in the liver. The decrease in the catalase enzyme is due to the buildup of free radicals caused by NaCl in the body. However, free radicals that are too excessive make catalase decrease and cannot function normally, and eventually damage liver cells. This is because in liver cells there are chromosomes [7].

Sodium chloride (NaCl) goes to the cell nucleus by penetrating the nuclear membrane, and chromatin condensation occur. At first there is a condensation of chromatin into a mass that makes the nucleus dark, round and smaller than normal [6]. This is following the research of [8];[9] which stated that the nucleus of

cells undergoing pyknosis is usually dark in color, and smaller than their normal size.

The result of the reaction of NaCl with fat making nuclear membrane destroys the cell nucleus and the chromatin is damaged and scattered in the cell nucleus. After the cell nucleus is destroyed, the chromatin dissolves. The cell nucleus becomes visible faintly and faded. This damage can cause the portal vein in the liver to experience this so that blood flow to the lungs cannot flow properly, resulting in various diseases such as hypertension [2].

4. Conclusion

Excessive consumption of sodium chloride make changes in the morphology of the liver and causes increased cell damage to the liver, the more doses are given, the more cells are damaged.

5. Acknowledgement

Thanks to all those who have supported this research, especially to my lecturers, this research would not have been possible without your prayers and support. Hopefully this research will provide many benefits for the community and other researchers.

References

- [1] Malhi H, Gores GJ. Cellular and molecular mechanisms of liver injury. *Gastroenterology*. 134(6):1641-1654. 2008.
- [2] Cotran, R., Kumar, V., & Collins, T. “*Pathology Basic of Disease 6th*”. Philadelphia; WB Saunders Co.P. 2007.
- [3] Rath KM, Maheshwari A, Bengtson P, Rousk J. Comparative Toxicities of Salts on Microbial Processes in Soil. *Appl Environ Microbiol*. 82(7):2012-2020. 2016.
- [4] Kurniawan, I. W. A. Y., Wiratmini, N. I., & Sudatri, N. W. “Histologi Hati Mencit (*Mus Musculus L.*) Yang Diberi Ekstrak Daun Lamtoro (*Leucaena Leucocephala*)”. *Jurnal Simbiosis*, 2(2), 226–235. 2014.
- [5] Tho N, Vromant N, Hung NT, Hens L. Organic pollution and salt intrusion in Cai Nuoc District, Ca Mau Province, Vietnam. *Water Environ Res*. 78(7):716-23. 2006.
- [6] Johnson GD, Lalancette C, Linnemann AK, Leduc F, Boissonneault G, Krawetz SA. The sperm nucleus: chromatin, RNA, and the nuclear matrix. *Reproduction*. 141(1): 21-36. 2011.
- [7] Celton-Morizur S, Desdouets C. Polyploidization of liver cells. *Adv Exp Med Biol*. 676:123-35. 2010.
- [8] Yaswir, R., & Ferawati, I. “Fisiologi dan Gangguan Keseimbangan Natrium, Kalium dan Klorida serta Pemeriksaan Laboratorium”. *Jurnal Kesehatan Andalas*, 1(2), 80–85. 2012.
- [9] Cahyaningrum, P., Windusari, Y. ., & Setiawan, A., Hippocampus cell disorders and neurosensory tests in mice (*Mus musculus*) due to induction of excess sodium chloride. *Biovalentia: Biological Research Journal*, 7(2): 97-100. 2021.

Vol. 8 No. 1 (2022)

Published: 06-03-2022

Vol 8, No 1 (2022): May 2022

AMPHIBIAN DISTRIBUTION ON DEGRADATED HABITAT IN PASIR BINTANG AND MANDURIANG DISTRICT GUNUNG RAYA WILDLIFE SANCTUARY AREA OF SOUTH SUMATRA PROVINCE

Aditya Yulistio, Zulkifli Dahlan, Zazili Hanafiah

1-5



PDF



DOI: <https://doi.org/10.24233/biov.8.1.2022.218>



| Abstract Views: **214** | PDF Downloads: **198** | Abstract & PDF: **412** |

DEVELOPMENT PROSPECTS OF BIOPHARMACEUTICAL PLANTS IN PALEMBANG CITY

Meri Ariyantini, Mirza Antoni, R Riswani

6-13



PDF



DOI: <https://doi.org/10.24233/biov.8.1.2022.238>



| Abstract Views: **150** | PDF Downloads: **127** | Abstract & PDF: **277** |

HISTOLOGY TEST OF TILAPIA (*Oreochromis niloticus*) ON ADSORBENT PERFORMANCE RESULTS IN LIQUID TREATMENT OF INDUSTRY PULP AND PAPER WASTE

Susila Arita Rachman, Devi Kristianti, Yuanita Windusari

14-21



PDF



DOI: <https://doi.org/10.24233/biov.8.1.2022.228>



| Abstract Views: **117** | PDF Downloads: **75** | Abstract & PDF: **192** |

ANTIOXIDANT ACTIVITY LEAVES KATIMAHA (*Kleinhovia hospita* L.)

Nova Elda Utami, Salni, Marieska Verawaty

22-31



PDF



DOI: <https://doi.org/10.24233/biov.8.1.2022.232>



| Abstract Views: **158** | PDF Downloads: **102** | Abstract & PDF: **260** |

PRIMER OPTIMIZATION AS GENETIC MARKER PRIMER BASED ON CYTOCHROME B GENE ON SUMATRAN ELEPHANT (*Elephas maximus sumatranus*) NON-INVASIVE SAMPLES

Eko Agus Srihanto; Elly Lestari Rustiati, Priyambodo, Dian Neli Pratiwi, Alvin Wiwiet Susanto, Diah Esti Anggraini, Enny Saswiyanti

32-35



PDF



DOI: <https://doi.org/10.24233/biov.8.1.2022.216>



| Abstract Views: **134** | PDF Downloads: **102** | Abstract & PDF: **236** |

GROWTH AND YIELD RESPONSE OF ARUMBA (*Zea mays* L. Ceratina) GLUTINOUS CORN VARIETIES TOWARD AMELIORANTS AND GROWTH REGULATORS ON PEATLAND

Railia Karneta, Nurlaili Fitri Gultom, Dewi Meidalima, Nyimas Manisah

36-42



PDF



DOI: <https://doi.org/10.24233/biov.8.1.2022.247>



| Abstract Views: **124** | PDF Downloads: **151** | Abstract & PDF: **275** |

SHORT COMMUNICATION: DAMAGE TO THE HISTOLOGICAL STRUCTURE OF MICE LIVER (*Mus musculus*) DUE TO EXCESSIVE CONSUMPTION OF SODIUM CHLORIDE

Rizqi Nur Ardiansyah, Arum Setiawan, Yuanita Windusari

43-45



PDF



DOI: <https://doi.org/10.24233/biov.8.1.2022.221>



| Abstract Views: **201** | PDF Downloads: **73** | Abstract & PDF: **274** |

INVESTIGATION OF LAND SUITABILITY FOR DUKU PLANTS AT RASUAN AND UJAN MAS IN SOUTH SUMATERA

Oktaf Juairiyah, Siti Masreah Bernas, Indra Yustian

46-50



PDF



DOI: <https://doi.org/10.24233/biov.8.1.2022.233>



| Abstract Views: **182** | PDF Downloads: **78** | Abstract & PDF: **260** |

HOUSING DESIGN WITH RAINWATER HARVESTING SYSTEM FOR HOUSING TYPE 36 AND TYPE 48

Deo Demai Kopaba, Widya Fransiska, Edward Saleh

51-60



PDF



DOI: <https://doi.org/10.24233/biov.8.1.2022.237>



| Abstract Views: **76** | PDF Downloads: **69** | Abstract & PDF: **145** |

POTENTIAL OF ACTIVE COMPOUNDS LEAVES OF MANGO PARASITE (*Dendrophthoe pentandra* (L. Miq) AS ANTIFUNGAL

M.Ridha Mauludi, Harry Widjajanti, Elisa Nurnawati

61-68



PDF

DOI: <https://doi.org/10.24233/biov.8.1.2022.245>| Abstract Views: **98** | PDF Downloads: **91** | Abstract & PDF: **189** |

INCREASING RICE PRODUCTIVITY IN DEGRADED PEATLANDS USING IMPROVED PLANTING METHODS AND RICE VARIETIES

Muhardianto Cahya, Rujito Agus Suwignyo, Erizal Sodikin, Himlal Baral
69-82



PDF

DOI: <https://doi.org/10.24233/biov.8.1.2022.246>| Abstract Views: **210** | PDF Downloads: **138** | Abstract & PDF: **348** |

ANTIBACTERIAL ACTIVITIES OF CIHERANG RICE (*Oryza sativa* L. Var. Ciherang) ETHANOL EXTRACT AGAINST Enterotoxigenic *Escherichia coli* (ETEC)

Dinda Sari, Bening Fitri Rini, Alifia Anisya, Feby Oktavia, Ali Zainal Abidin, Marieska Verawaty
83-87



PDF

DOI: <https://doi.org/10.24233/biov.8.1.2022.239>| Abstract Views: **218** | PDF Downloads: **108** | Abstract & PDF: **326** |

Sunday, November 27, 2022 18:19

WELCOME VISITORS

MENU

ADDITIONAL MENU



SUPPLEMENTARY FILES



TEMPLATE

JOURNAL INDEXING

JOURNAL HISTORY


PLAGIARISM DETECTION

Editorial Team

Editor in Chief



 **Dr. Sarno, M.Si.**

 Scopus ID: [7409562485](#)

 Sinta ID: [259870](#)

 Biology Department, Sriwijaya University, Indonesia

Managing Editor



 **Drs. Enggar Patriono, M.Si.**

 Scopus ID: [57210575054](#)

 Sinta ID: [5975551](#)

 Biology Department, Sriwijaya University, Indonesia


Editors



 **Dr. Haryono, M.Si.**

 Scopus ID: [57211269738](#)

 Google Scholar ID: [OA83KacAAAAJ](#)

 Zoology Department, Research Center for Biology, Indonesian Institute of Sciences, Indonesia



Dr. Wilson Novarino, M.Si.



Scopus ID: [55710775000](#)



Sinta ID: [5992358](#)



Biology Department, Andalas University, Indonesia



Dr. Zazili Hanafiah, M.Sc.



Scopus ID: [57205020007](#)



Sinta ID: [6117602](#)



Biology Department, Sriwijaya University, Indonesia



Drs. Agus Purwoko, M.Sc.



Scopus ID: [57205655041](#)



Google Scholar ID: [Pxx7R-QAAAAJ](#)



Biology Department, Sriwijaya University, Indonesia



Dr. Arum Setiawan, M.Si.



Scopus ID: [57199292527](#)



Sinta ID: [5982102](#)



Biology Department, Sriwijaya University, Indonesia



Dr. Laila Hanum, M.Si.



Scopus ID: [57194601647](#)



Sinta ID: [5981739](#)



Biology Department, Sriwijaya University, Indonesia



Dr. Elisa Nurnawati, M.Si.



Scopus ID: [57211883518](#)



Sinta ID: [5980528](#)



Biology Department, Sriwijaya University, Indonesia

Section Editors



Dr. Rahmat Pratama, S.Si.



Scopus ID: [57208525728](#)



Google Scholar ID: [4_ZFE_IAAAAJ](#)



Biology Department, Sriwijaya University, Indonesia



Dwi Puspa Indriani, S.Si., M.Si.



Google Scholar ID: [E4f1s8kAAAAJ](#)



Sinta ID: [6117986](#)



Biology Department, Sriwijaya University, Indonesia



Doni Setiawan, S.Si., M.Si.



Scopus ID: [56108427300](#)



Sinta ID: [6078378](#)



Biology Department, Sriwijaya University, Indonesia

Sunday, November 27, 2022 18:18

WELCOME VISITORS

SERTIFIKAT

Direktorat Jenderal Penguatan Riset dan Pengembangan,
Kementerian Riset, Teknologi, dan Pendidikan Tinggi



Kutipan dari Keputusan Direktur Jenderal Penguatan Riset dan Pengembangan,
Kementerian Riset, Teknologi, dan Pendidikan Tinggi Republik Indonesia
Nomor: 10/E/KPT/2019
Tentang Hasil Akreditasi Jurnal Ilmiah Periode 2 Tahun 2019

BIOVALENTIA: Biological Research Journal

E-ISSN: 24771392

Penerbit: Biology Department, Faculty of Mathematics and Natural Sciences, Sriwijaya University

Ditetapkan sebagai Jurnal Ilmiah

TERAKREDITASI PERINGKAT 3

Akreditasi berlaku selama 5 (lima) tahun, yaitu
Volume 4 Nomor 2 Tahun 2018 sampai Volume 9 Nomor 1 Tahun 2023

Jakarta, 4 April 2019

Direktorat Jenderal Penguatan Riset dan Pengembangan

