

Calcipenic Rickets Accompanied by Hypercoagulability, Hypokalemia and a History of Secondary Amenorrhea: A Case Report

by Radiyati Umi Partan


Submission date: 03-Apr-2023 09:15PM (UTC-0500)

Submission ID: 2055197869

File name: 290._Manuscript_Radiyati_Umi_Partana_et_al.docx (5.89M)

Word count: 2420

Character count: 13126



Calcipenic Rickets Accompanied by Hypercoagulability, Hypokalemia and a History of Secondary Amenorrhea: A Case Report

Radiyah Umi Partan^{1*}, Merylla Filianty Sipayung², Ratna Maila Dewi³

¹Division of Rheumatology, Department of Internal Medicine, Faculty of Medicine, Universitas Sriwijaya/Dr. Mohammad Hoesin General Hospital, Palembang, Indonesia

²Subspecialized Residency Training of Endocrine Metabolic Disease and Diabetes, Department of Internal Medicine, Faculty of Medicine, Universitas Sriwijaya/Dr. Mohammad Hoesin General Hospital, Palembang, Indonesia

³Division of Endocrine Metabolic Disease and Diabetes, Department of Internal Medicine, Faculty of Medicine, Universitas Sriwijaya/Dr. Mohammad Hoesin General Hospital, Palembang, Indonesia

ARTICLE INFO

Keywords:

Calcium
Hypercoagulation
Hypokalemia
Rickets
Vitamin D

*Corresponding author:

Radiyah Umi Partan

E-mail address:

radiyah.u.p@fk.unsri.ac.id

All authors have reviewed and approved the final version of the manuscript.

<https://doi.org/10.37275/amcr.v4i2.290>

ABSTRACT

Rickets is a metabolic disease as a result of inadequate bone mineralization. This case report aims to present a patient with calcipenic rickets, which are accompanied by hypercoagulability, hypokalemia, and secondary amenorrhea. In this case, a woman, 21 years old, unmarried, living outside the city of Palembang, came to the endocrine polyclinic with complaints of leg pain, making it difficult to walk along with growth retardation. In addition, there is a lump on the right arm and left knee that does not enlarge, height and weight do not increase, and both legs are bent. Based on physical examination, the general condition looked moderately ill, with vital signs within normal limits, body weight 26 kg, height 123 cm, and body mass index 17.8 kg/cm². In the superior extremity, a 2-3 cm mass was found in the right humerus. In the lower extremities, there was a mass measuring 3 cm in the left lateral genu, supple and easy to move, with no pain. On examination of genital maturity, Tanner 2 was found. Laboratory evaluation results at the first visit to the endocrine clinic showed increased fibrinogen, d-dimer level, parathyroid hormone, and alkaline phosphatase. In addition, there was a decrease in calcium, potassium, vitamin D-25 OH, phosphorus, growth hormone, and anti-Mullerian hormone. Bone examination shows bone age according to girls aged 15 years. The patient was diagnosed with calcipenic type rickets with hypercoagulability, hypokalemia, and secondary amenorrhea. Initial management is given calcium 500-4000 g/day, potassium 40-100 mEq/24 hours, warfarin 2 mg/24 hours, acetylsalicylic acid 80 mg/24 hours, vitamin D 1000 mg/24 hours, CaCO₃ 500 mg/8 hours, potassium chloride 600 mg/12 hours. In conclusion, cases of rickets are quite rare and require further examination to establish a diagnosis.

1. Introduction

Rickets is a disease characterized by impaired mineralization of the bone matrix. Rickets developing before the closure of the bone growth plates mostly affect the long bones and cause poor bone growth and poor bone mineralization and leading to bone

deformities. This disease has been classified as a metabolic bone disease.¹ Epidemiology rickets in Indonesia has not been found clearly. There are only data regarding vitamin D deficiency in children in Indonesia. The epidemiology of rickets is increasing in developing countries compared to developed countries.



Mortality from rickets is related to complications from vitamin D deficiency and increases with the severity of vitamin D deficiency.^{2,3}

Vitamin D is very important for bone health. Vitamin D affects the absorption of calcium and phosphorus, which help to mineralize bones. A deficiency of Vitamin D prevents the absorption of calcium and phosphorus. In vitamin D deficiency, only 10-15% of dietary calcium and 50-60% of dietary phosphorus is absorbed. This can result in hypocalcemia or hypophosphatemia, so vitamin D stimulates bone resorption to maintain serum calcium and phosphorus levels. Hypocalcemia results in the increased synthesis and secretion of parathyroid hormone.^{3,4} This case report aimed to present a patient with calcipenic rickets accompanied by hypercoagulability, hypokalemia, and secondary amenorrhea.

2. Case Presentation

A woman, 21 years old, unmarried, living outside the city of Palembang, came to the endocrine polyclinic Dr. Mohammad Hoesin General Hospital with complaints of leg pain, making it difficult to walk along with growth retardation. Complaints of pain in the limbs started 9 years ago, accompanied by cramps, tingling, and weakness. At that time, the patient was treated at a local hospital and was hospitalized with a diagnosis of lack of potassium.

Seven years ago, the patient experienced a growth disorder where the height and weight did not increase.

Complaints of leg pain are still there and accompanied by nausea. The patient was re-admitted to the hospital. Five years ago, the patient complained of a lump on her left knee and upper arm. The lump is the size of a ping pong ball on the left knee and the size of a marble on the upper right arm. This lump is not painful. The patient's legs began to bend, and it was difficult to walk. Four years ago, the patient complained of not menstruating. At that time, the patient was in the eleventh grade of vocational high school. The patient's first menstruation was at the age of 13 years.

Since 3 years ago, there are still complaints of difficulty walking, body weakness, and lumps on the right arm and left knee that is not enlarged. The patient's height and weight did not increase. Both legs are crooked, and the patient is difficulty walking and activity. The patient has experienced menstruation again. During the last 2 years, the patient only went to alternative medicine and not to the hospital.

Based on physical examination, the general condition looked moderately ill, with vital signs within normal limits, body weight 26 kg, height 123 cm, and body mass index 17.8 kg/cm². Examination of the heart and lungs within normal limits. In the superior extremity, a 2-3 cm mass was found in the right humerus. In the lower extremities, there was a mass measuring 3 cm in the left lateral genu, supple and easy to move, painless, and the shape of the foot was genu valgum. On examination of genital maturity, Tanner 2 was found (Figure 1).

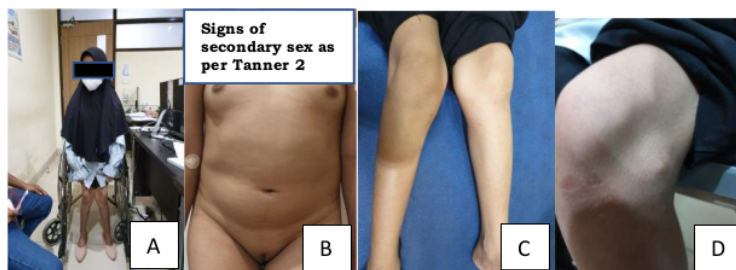


Figure 1. (A-D) Patient's clinical condition.



Laboratory evaluation results at the first visit to the endocrine polyclinic showed increased fibrinogen levels (535 mg/dL), d-dimer levels increased by 1.21 ug/mL, blood potassium levels decreased (2.3 mEq/L), blood calcium levels decreased (8.3 mg/dL), parathyroid hormone (PTH) level increased (1127.80 pg/mL), insulin-like growth factor-1 (IGF-1) decreased (48 ng/mL), decreased vitamin D-25 OH level (26.2 ng/mL), alkaline phosphatase increased (1787 U/L), phosphorus level decreased (2.0 mg/dL), growth hormone decreased (0.22 ng/mL) and decreased anti-Mullerian hormone (3.48 ng/ml). Electrocardiography (ECG) examination showed sinus rhythm and

hypokalemia. Genu magnetic resonance imaging (MRI) examination showed pathological defects in the distal metaphysis of the femur and proximal metaphysis of the tibia and fibula; there is minimal joint effusion on the retropatella; lobulated cyst measuring 3.6x1.5 cm in the subcutis of the lateral condyle of the femur (Figure 2). Bone survey examination showed suspected thoracic scoliosis to the right, lytic blastic lesions in the proximal 1/3 of the right and left femur with suspicion of fracture, and fractures of the proximal 1/3 of the right and left humerus (Figure 3). Bone age examination shows bone age according to a 15-year-old girl (Figure 4).

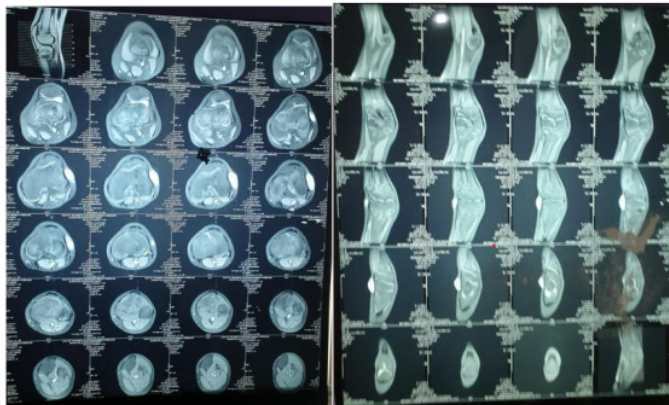


Figure 2. Genu MRI examination.

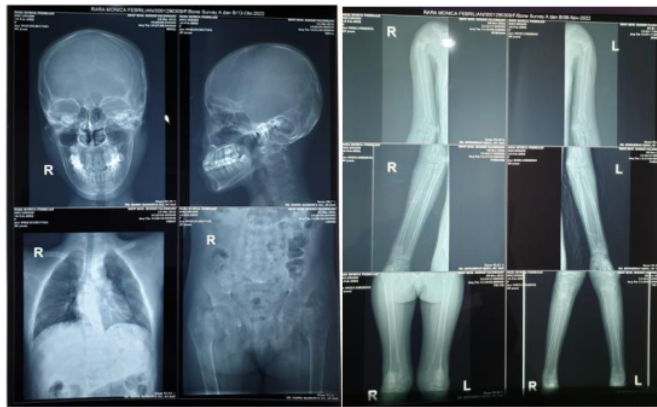

Figure 3. Photo of the bone survey.

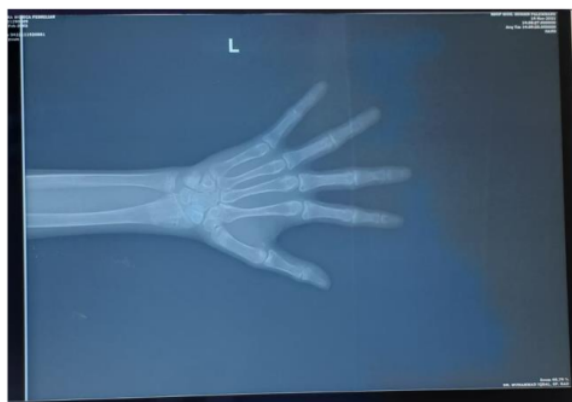

Figure 4. Photo of bone age.

Based on anamnesis, physical examination, and investigations, the patient was diagnosed with calcipenic rickets (the differential diagnosis was Turner syndrome) accompanied by hypercoagulability, hypokalemia, and secondary amenorrhea. Initial management is given calcium 500-4000 g/day, potassium 40-100 mEq/24 hours, warfarin 2 mg/24 hours, acetylsalicylic acid 80 mg/24 hours, vitamin D 1000 mg/24 hours, CaCO_3 500 mg/8 hours, potassium chloride 600 mg/12 hours.

The patient was consulted at the rheumatology polyclinic at the control visit 2 weeks later, and a bone marrow density (BMD) examination was performed. The results of bone marrow density examination on the AP spine obtained a Z-score -4.7, BMD on the left forearm obtained a z-score -9.5; BMD on the left femur obtained Z-score -3.8. This BMD result was very low based on the age and gender of the patient. The rheumatology division recommends increasing the dose of vitamin D to 5000 IU/24 hours.

In the next 1 week control, the patient was consulted at the hematology polyclinic for indications of hypercoagulation. The patient was then given warfarin 4 mg/24 hours. However, 2 weeks later, the patient came back with complaints of bruising on both hands, so he was given warfarin and acetylsalicylic acid suspended.

2 months later, the chromosomal analysis showed no abnormalities in chromosome structure and number. Karyotype according to the female gender. The cell count has been added to 100 cells, and no cells with monosomy X (45,X) were found. Mosaicism with a very low number of abnormal cells (sex chromosomes) is sometimes not caught on this test. Syndromic short stature (SS) is reported to be caused by chromosomal aberrations on the X and autosomes, while isolated SS without other symptoms or non-syndromic causes varies widely. Chromosomal analysis cannot exclude <5Mb and other DNA abnormalities. Chromosomal microarrays (CMA) can detect the gain and loss of DNA sequences (microdeletion). This patient was previously diagnosed with calcipenic rickets, which was diagnosed in differential with Turner syndrome. With the results of this chromosomal analysis, there was no Turner syndrome.

3. Discussion

Rickets is a bone metabolic disease as a result of inadequate bone mineralization. This can occur because there are disturbances in the metabolism of calcium, phosphorus, and vitamin D. Rickets usually affects pregnant women, infants, children, and adolescents who live in areas with inadequate



exposure to sunlight, as well as low food intake. Contains vitamin D.⁵ One result of vitamin D deficiency is stunted growth and short stature. This patient had growth retardation and short stature. Short stature can be caused by condition pathological and non-pathological, so it is important to know how to approach clinical cases of short stature.⁶

The patients were found to have short stature and abnormal growth rates. Rickets causes disruption of the metabolism of vitamin D, calcium, and phosphate. Vitamin D is an essential nutrient for the body to absorb calcium. Vitamin D is an essential steroid hormone that plays a role in maintaining calcium and phosphate hemostasis. Vitamin D does not come entirely from food, but most of it is produced in the epidermis of the skin by exposure to ultraviolet B (UVB) radiation. Only a small part, or 5%, of vitamin D, comes from food sources.^{7,8}

Early in the course of rickets, the concentration of serum calcium levels will decrease. After the oversecretion of parathyroid hormone occurs, the calcium concentration usually returns to the normal range, although the level of phosphate remains low. Alkaline phosphates are produced by cells' osteoblasts. Those that are too active will come out into the extracellular fluid, so the concentration of alkaline phosphatase will rise. In patients with hypocalcemia, calcium levels were 7.34 mg/dl, and an increase in parathyroid hormone levels was 1127.80 pg/ml. Low levels of phosphorus 2.0 mg/dl, an increase of alkaline phosphatase 1787 U/L, and low levels of Vitamin D-25 OH 26.2 ng/ml.

Vitamin D is an essential nutrient for the body to absorb calcium. If there is a deficiency of vitamin D, then the absorption of calcium will be reduced, and if the intake of calcium is also reduced it will cause a deficiency of calcium in the body, which will cause hyperparathyroidism. This increase in parathyroid hormone will cause phosphaturia and low serum phosphate levels. This situation can cause abnormal bone mineralization. Abnormal bone mineralization in

the bony plates will cause several bone disorders, such as rickets. In the anamnesis, there were complaints of cramps and pain in both legs, crooked legs, and the patient had difficulty walking, and there was growth disturbance. On physical examination, growth was found that did not match the patient's age, seen from height and weight. This was confirmed by bone age examination, where the results were obtained according to the age of 15 years while this patient was already 20 years old. In patients also found the condition extremity inferior genu valgum. The patient's rickets was of the calcipenic type caused by vitamin D deficiency.

These patients have low calcium levels, where calcium is required in the coagulation cascade. The hypercoagulable state in these patients can be caused by disruption of the coagulation cascade pathway due to the low calcium levels in these patients.^{9,11} During outpatient treatment, the patient received warfarin tablets 2 mg per day and was evaluated for hemostasis physiology.

This patient also has hypokalemia. Hypokalemia is a condition characterized by low serum potassium concentrations. Hypokalemia can result from a shift of potassium from the extracellular to the intracellular space (internal balance) or from the depletion of potassium due to loss into the digestive tract or urine (external balance). In evaluating the diagnosis of hypokalemia, the first step is to rule out pseudo hypokalemia or extracellular to intracellular K redistribution. Furthermore, the diagnosis of the cause of hypokalemia in this patient was carried out by excluding the drug factor because, from the history, it was known that there was no history of using aminoglycosides or platinum drugs in the patient. This patient had normal blood pressure. Thus, the probable cause of hypokalemia in this patient is extra-renal. Giving potassium is preferred in oral form because it is easier. Giving 40-60 mEq can increase potassium levels by 1-1.5 mEq/L, while giving 135-160 mEq can increase potassium levels by 2.5-3.5mEq/L.¹²⁻¹⁶

Secondary amenorrhea is a condition where menstruation does not occur for 3 consecutive menstrual cycles or within a period of 6 months in women who previously had normal menstrual cycles. This patient had her first menstruation at the age of 15 and did not experience menstruation during the eleventh grade of vocational high school. The patient experienced menstruation again at the age of 20 years. Most cases of secondary amenorrhea are caused by low or normal FSH levels, such as anorexia, nonspecific hypothalamic, and chronic anovulation (PCOS, hypothyroidism, and pituitary tumors), besides that there are also events caused by high levels of FSH, such as ovarian premature due to abnormal karyotype (45, XO) and gonadal dysgenesis, high prolactin levels, due to anatomic abnormalities (Asherman's syndrome) and also caused by condition hyperandrogenic such as PCOS and ovarian tumors.¹⁷ In this patient, FSH, LH, and prolactin hormone examinations were carried out, and normal hormone levels were obtained. Estradiol and anti-Mullerian hormone (AMH) levels were low in this patient, where estradiol levels were 10pg/ml and AMH 3.48 ng/ml. AMH examination is carried out to determine the ovum reserves in patients.

4. Conclusion

Cases of rickets are quite rare cases and require further examination to establish a diagnosis. The lack of information and research regarding this disease and its management is too late. The quality of life of patients affected by rickets can be severely disrupted due to muscle weakness and bone pain resulting in limited physical activity in patients.

5. References

1. Carpenter TO, Shaw NJ, Portale AA. Rickets. *Journal of Nature Reviews Disease Primers*. 2017; 3: 1710
2. Chanchlani R, Nemer P, Sinha R, Nemer L, Krishnappa V, Sochett E. An overview of rickets in children. *Journal of Kidney International Reports*. 2020; 5(7): 980-90
3. Ernawati F, Budiman B. Current vitamin D status of Indonesian children aged 2.0-12.9 years. *Gizi Indon* 2015; 38(1): 73-80
4. Wheeler BJ, Snoddy AM, Munns C, Simn P, Siafarikar A, Jefferies C. A brief history of nutritional rickets. *Journal of Frontiers in Endocrinology*. 2019; 10: 1-4.
5. Haffner D, Leifheit-Nestler M, Grund A, Schnabel D. Rickets guidance: Part 1-diagnostic workup. *Pediatric Nephrology*. 2022; 37: 2013-36
6. Jose R, Hardjoedi A, Aditiawati. Short stature in children and adolescents in Indonesia. *Ikatan Dokter Anak Indonesia*. 2017.
7. Holick MF. Resurrection of vitamin D deficiency and rickets. *J Clin Invest*. 2020
8. Manisha S, Rakesh S. Rickets-vitamin D deficiency and dependency: Review article. *Indian Journal of Endocrinology and Metabolism*. 2012; 16: 166.
9. Jessica P, Luciano P, Federica B, Chiara S, Vittoria CN, Veronica C, et al. Diagnosis and management of hypocalcemia. Article in *Endocrine*. 2020; 9: 6-7
10. Fukumoto S, Ozuno K, Michigami T, Minagawa M, Okazaki R, Sugimoto T. Pathogenesis and diagnostic criteria for rickets and osteomalacia. *Journal of Endocrinology*. 2015; 62(8): 665-71
11. Prentice A. Nutritional rickets around the world. *Journal of Steroid Biochemistry Molecular Biology*. 2013; 136: 201-6
12. Acar S, Demir K, Shi Y. Genetic causes of rickets. *Journal of Clinical Research in Pediatric Endocrinology*. 2017; 9(2): 88-105
13. Jagtap VS, Sarathi V, Laila AR. Hypophosphatemic rickets. *Indian Journal of Endocrinology Metabolism*. 2012; 16: 177-82
14. Helmi I, Rani H, Maula AF. Rickets: A literature review. *Medula*. 2021; 10: 649.



- 13
15. Weiner I.D, Wingo C.S. Hypokalemia-
consequences, causes and correction. Journal
of the American Society of Nephrology. 2005; 8:
1179-80
- 12
16. Unwin RJ, Left FC, Shirley DG. Pathophysiology
and management of hypokalemia: A Clinical
Perspective. Nat Rev Nephrol. 2011; 7(2): 75-84
- 7
17. Moolhuijsen LME, Visser JA. Anti-Mullerian
hormone and ovarian reserve: update on
assessing ovarian function. J Clin Endocrinol
Metab. 2020; 105(11): 3361-73.



Calcipenic Rickets Accompanied by Hypercoagulability, Hypokalemia and a History of Secondary Amenorrhea: A Case Report

ORIGINALITY REPORT

18%

SIMILARITY INDEX

15%

INTERNET SOURCES

13%

PUBLICATIONS

13%

STUDENT PAPERS

PRIMARY SOURCES

- 1 jipd.uhamka.ac.id 3%
Internet Source
- 2 Raymond Pranata, Alexander Edo Tondas, Emir Yonas, Veresa Chintya, Muhammad Yamin. "Efficacy and safety of catheter ablation for atrial fibrillation in congenital heart disease – A systematic review and meta-analysis", Indian Pacing and Electrophysiology Journal, 2019 1%
Publication
- 3 Mamta Chhabria, Ignacio Portales-Castillo, Medhat Chowdhury, Atif Sohail et al. "A Case of Severe Hypokalemia", American Journal of Kidney Diseases, 2020 1%
Publication
- 4 Submitted to University of Western Australia 1%
Student Paper
- 5 Submitted to Manchester Metropolitan University 1%

6	repository.unimal.ac.id Internet Source	1 %
7	reproductive-health-journal.biomedcentral.com Internet Source	1 %
8	docplayer.net Internet Source	1 %
9	hvm.bioflux.com.ro Internet Source	1 %
10	Siraj Muneer, Imran Siddiqui, Hafsa Majid, Nawazish Zehra, Lena Jafri, Aysha Habib Khan. "Practices of vitamin D supplementation leading to vitamin D toxicity: Experience from a Low-Middle Income Country", <i>Annals of Medicine and Surgery</i> , 2022 Publication	1 %
11	Submitted to University of Pittsburgh Student Paper	1 %
12	link.springer.com Internet Source	1 %
13	Submitted to National University of Singapore Student Paper	1 %
14	akper-sandikarsa.e-journal.id Internet Source	1 %

15	Submitted to Endeavour College of Natural Health Student Paper	1 %
16	Deivert, Stephanie, and Christopher Still. "Metabolic Bone Disease Following Bariatric Surgery", Nutrition and Bariatric Surgery, 2014. Publication	1 %
17	Submitted to Regis College Student Paper	1 %
18	www.scielo.cl Internet Source	1 %
19	topsecretapiaccess.dovepress.com Internet Source	1 %
20	www.slideshare.net Internet Source	<1 %
21	Submitted to Australian Catholic University Student Paper	<1 %
22	adoc.pub Internet Source	<1 %
23	patents.google.com Internet Source	<1 %
24	"Essentials of Palliative Care", Springer Nature, 2013 Publication	<1 %

25 Puspa Zuleika. "A Case of Whistle as Foreign Body in Trachea", Bioscientia Medicina : Journal of Biomedicine and Translational Research, 2021
Publication <1 %

26 www.springermedizin.de
Internet Source <1 %

27 Hartati, Febi Stevi Aryani, M Satria Erlangga Sinum, Emasrissa Murwani. "Surgical Site Infection Post Caesarean Section: A Case Report", Bioscientia Medicina : Journal of Biomedicine and Translational Research, 2021
Publication <1 %

28 Pallavi Iyer, Frank B. Diamond. "Shedding Light on Hypovitaminosis D and Rickets", Advances in Pediatrics, 2007
Publication <1 %

29 "Vitamin D", Walter de Gruyter GmbH, 1994
Publication <1 %

Exclude quotes Off

Exclude matches Off

Exclude bibliography Off