

# Indonesian Journal of Rheumatology

*by* Dr. Dr. Radiyati Umi Partan, Sppd Kr -

---

**Submission date:** 07-Apr-2023 05:11AM (UTC-0700)

**Submission ID:** 2058336213

**File name:** 5\_6160924633840224576.pdf (723.29K)

**Word count:** 4760

**Character count:** 26098



## 40 Adult-Onset Still's Disease (AOSD): A Case Report

Muhammad Reagan<sup>1</sup>, Radiyati Umi Partan<sup>1\*</sup>

<sup>36</sup>  
<sup>1</sup> Division of Rheumatology, Department of Internal Medicine, Universitas Sriwijaya, Palembang, Indonesia

### ARTICLE INFO

#### Keywords:

Adult-Onset still's disease  
Hyperferritinemia  
Amenorea

#### Corresponding author:

Radiyati Umi Partan

E-mail address:

[radiyati.u.p@fk.unsri.ac.id](mailto:radiyati.u.p@fk.unsri.ac.id)

All authors have reviewed and approved the final version of the manuscript.

<https://doi.org/10.37275/IJR.v14i1.196>

### ABSTRACT

**Introduction.** Adult-Onset Still's Disease (AOSD) is a rare multisystemic autoinflammatory disorder with an unknown etiology and the diagnosis is difficult due to various differential diagnoses. AOSD diagnosis is getting better because medical developments and therapeutic strategies from various studies have benefited from advances in understanding autoinflammatory and autoimmune diseases. **Case Presentation.** A woman patient has a complaint of periodic high fever with joint pain for more than 1 month and reddish spots on the skin, fatigue and menstrual disorders. Patients had been treated several times and performed a blood transfusion, but complaints still occur frequently. The patient is diagnosed as Adult-Onset Still's Disease with secondary amenorrhoea. **Conclusion.** This case is rarely found, so it requires quite difficult therapy and diagnostics. Therefore, this case was presented as a case report in order to get better therapy.

## 31 1. Introduction

Adult-Onset Still's Disease (AOSD) is a rare multisystemic autoinflammatory syndrome or disorder that is still not widely known by health practitioners. The autoinflammatory syndrome consists of a series of distinct clinical disorders united by recurrent episodes of fever, accompanied by various inflammatory manifestations of the skin, mucosa, serosa, or osteoarticular.<sup>1</sup> Although this rare disorder often has a clear onset and inflammatory features, no cause is identified. infectious or autoimmune.<sup>2,3,4</sup> Developments in the diagnostics of AOSD will get better with advances in diagnostic support, and therapeutic strategies from various studies have been carried out with various advances in the understanding of auto-inflammatory and autoimmune diseases.<sup>1</sup>

Epidemiological data on AOSD is still lacking,

especially In Indonesia, not many people know about it. The disease is reported worldwide and usually affects young adults (mean age at diagnosis is about 36 years) although the disease can still be detected up to the age of 83 years. The incidence is estimated at 0.16 (per 100,000 people) in France, 0.22 in Japan, and 0.4 in Norway. In Japanese and European populations, reported prevalence rates range from 1 to 34 cases per 1 million people. Based on serial rheumatology cases, the incidence is more common in women than men, which is up to 70% of patients. However, it is different again if the case series is special in the department of internal medicine, then women are found in only 45 to 53% of patients.<sup>1</sup>

Although no familial trend has been reported in AOSD, several studies have shown an association of AOSD with HLA antigens. A Survey of 55 patients

from Canada, by Pouchot et al.,<sup>4</sup> described a strong relationship between AOSD and HLA-B\*17, -B\*18, -B\*35, and -DR2. In a Japanese study, HLA-DRB1\*1501 (DR2) and HLA-DRB1\*1201 (DR5) showed an association with chronic AOSD while HLA-DQB1\*0602 (DQ1) also showed an association with chronic and systemic AOSD.<sup>1</sup>

The Korean study compared 47 AOSD cases with 144 healthy controls focusing on the HLA-DRB1 genotype. AOSD patients tend HLA-DRB1\*12 and -DRB1\*15, but HLA-DRB1\*04 is rare.<sup>5,7</sup> In conclusion, there are no consistent results from association studies between AOSD and the HLA locus. This may be the result of the wide heterogeneity associated with various ethnic groups. A recent study in Japan that evaluated gene polymorphisms in interleukin (IL)-18, found that the frequency of the S01/S01 diplotype configuration was significantly higher in AOSD patients than controls.<sup>1</sup>

Infectious disease was also suspected to play a role because of the similar clinical presentation between AOSD and infectious diseases such as sudden onset, high fever, lymphadenopathy, splenomegaly, and leukocytosis. Involvement of microorganisms such as viruses (rubella, measles, Echovirus 7, Coxsackievirus B4, Cytomegalovirus, Epstein-Barr virus, Human herpesvirus 6, Parainfluenza, Influenza A, Adenovirus, hepatitis B and C, and Parvovirus B19) and bacteria (Mycoplasma pneumonia, Chlamydia pneumonia, Yersinia enterocolitica, Brucella abortus, and Borrelia burgdorferi) have also been isolated from patients with AOSD, but the scientific evidence remains unclear.<sup>1</sup>

Infection may trigger interactions with host genetic factors, mechanisms of autoimmunity, and pathogenic antigens, ultimately leading to a role in disease pathogenesis. In addition, 28 cases of AOSD-like disease were associated with malignancies including solid cancer (60% of cases, mainly breast and lung) and hematological malignancies (40%, lymphoma).<sup>1</sup>

This scientific case report is about a woman with Adult Onset Still's Disease. This report is appointed as a rare case, and various follow-up steps are needed in terms of diagnostics and management, hopefully, it will be useful and add to our knowledge together.

## 2. Case Presentation

A woman, Ms. SYT, 20 years old, Muslim, not working, last education bachelor degree, address Jln. Pulo Gadung High Court Km 11, Palembang city. The patient was brought to the RSMH ER on October 15, 2019, and treated in Rupit Room 1.1, room 2.3 since October 15, 2019, with the main complaint of feeling weak since 5 days of SMRS, and additional complaints of high fever coming and going.

About ±8 months ago the patient complained of high fever coming and going for more than 7 days. Complaints of a red rash on both cheeks, no hair loss than usual, no thrush, no red face when exposed to sunlight, no weakness, no light-headedness, no shortness of breath, nosebleeds and gums No bleeding, no seizures, no headache, no weakness in the limbs, no tingling, no joint pain, Urinating and defecating there were no complaints. The patient went to a general practitioner and received 3 days of treatment in the form of antibiotics and fever medicine, but there was no improvement. Patients who go to the emergency room of a private hospital and are hospitalized by the SpPD for 5 days are said to be typhoid, then go home with improvement.

About ±7 months ago or 2 weeks after treatment, the patient again complained of intermittent high fever accompanied by reddish patches appearing on the body without itching or pain. Complaints of a red rash on both cheeks, no hair loss than usual, no thrush, no red face when exposed to sunlight, no weakness, no light-headedness, no shortness of breath, nosebleeds and gums No bleeding, no seizures, no headache, no weakness in the limbs, no tingling, no joint pain, Urinating and defecating there were no complaints. The patient went to a private hospital to be treated for 5 days and received

treatment in the form of antibiotics and fever medicine, but there was no improvement. The patient was referred to RSMH Palembang and hospitalized for 7 days was said to have a urinary tract infection, then went home with improvement.

About ± 6 months ago the patient again complained of high fever coming and going. The patient is easily limp and decreased appetite. Complaints of a red rash on both cheeks, no hair loss than usual, no canker sores, no red face when exposed to sunlight, no light-headed vision, no tightness or pounding, no nosebleeds, and bleeding gums. There were no seizures, no headaches, no weakness in the limbs, no tingling sensations, no joint pain, Urinating and defecating there were no complaints. The patient was brought to the ER RSMH and hospitalized for 7 days, said to be anemic with inflammation in the body, then returned home with improvement after a transfusion of blood and further control through the polyclinic.

About ±1 month ago the patient again complained of high fever coming and going. The patient is easily weak and dizzy, as well as decreased appetite. Dark patches on the skin at the site of the previous rash. Complaints of a red rash on both cheeks, no hair loss than usual, no thrush, no red face when exposed to sunlight, no shortness of breath, no nosebleeds and bleeding gums, no sore throat, urination and defecation there were no complaints. The patient complained of pain in the joints in both wrists and feet and fingers. The patient was brought to the ER of RSMH and hospitalized for 7 days and was said to have anemia and immune disorders. The patient received a transfusion of blood and then went home with repair and control through the polyclinic.

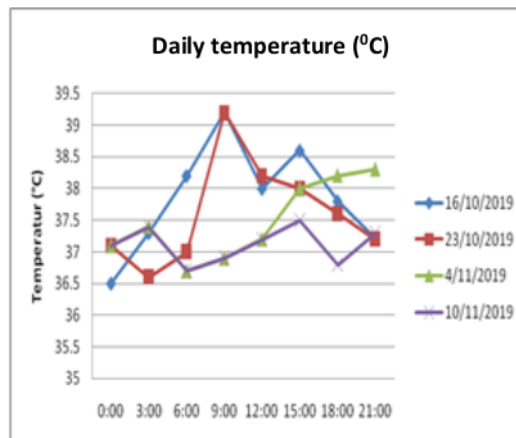
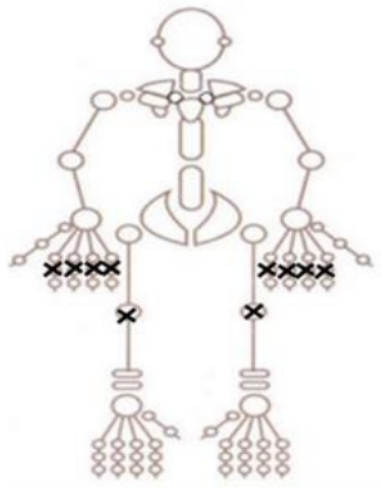
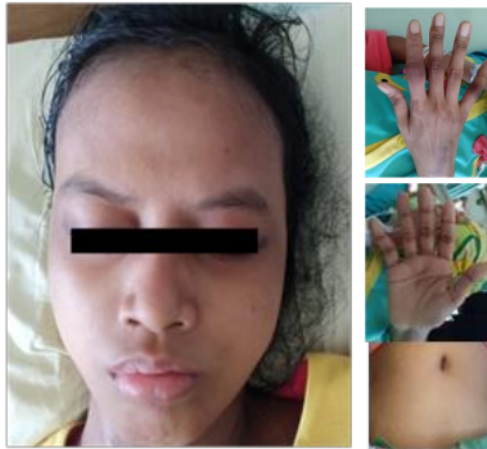After ± 5 days of SMRS, the patient again complained of high fever coming and going. The patient is easily weak and dizzy, as well as decreased appetite. The patient complains of pain in both knee joints and knuckles of both hands. Complaints of a

red rash on both cheeks, no hair loss than usual, no thrush, no redness on the face when exposed to sunlight, no light-headed vision, no cough and shortness of breath, no nosebleeds and bleeding gums. There were no seizures, no headaches, no weakness in the limbs, no tingling sensations, no sore throat, no swelling or lumps on the body, Urinating and defecating there were no complaints. Prolonged cough and drastic weight loss, as well as night sweats, are absent. The patient was taken to the emergency department of RSMH Palembang.

Past medical history such as jaundice/liver, malignancy/tumor, high blood pressure, heart disease, blood disorders, lung disease/tuberculosis was denied. History of habits such as smoking, drinking alcohol, IDU, drugs, and exposure to chemicals/toxics was denied. History of drug/food allergy was denied. He denied a family history of diseases such as malignancy and blood disorders and denied contact with TB patients. History of the first menstruation at the age of 14 years and regular cycles every month. Socio-economic history: the patient is unmarried, recently graduated from undergraduate education, lives with his mother who owns a canteen business with an average income of around 3 million per month. The patient is treated using BPJS class I. The patient is the second child of two siblings.

On physical examination, *sensorium compos mentis* was found, general condition appeared moderately ill, blood pressure 120/70 mmHg, pulse 112 times/minute regular, respiration 22 times/minute, temperature 38.6 °C, VAS 3, weight 49 kg, height body 165 cm, BMI 18.03 kg/m<sup>2</sup>.

Specific conditions of the head: pale palpebral conjunctiva and hyperpigmentation of the eyelids were found, there was oral thrush. Examination of the extremities found arthralgia and swelling according to the location image.



On laboratory examination (15/10/2019) routine blood, Hb 4.8 g/dL; erythrocytes 2.16 million/mm<sup>3</sup>; leukocytes 7.260/mm<sup>3</sup>; Ht 15%; platelets 114,000/ $\mu$ L; DC 0/1/75/17/7; MCV 67.6 fL; MCH 22 pg; MCHC 33 g/dL; LEDs 20 mm/hour; Malaria negative.

Peripheral blood picture: microcytic erythrocytes, hypochromic, flash cells, pencil cells, cell fragments, anisopoikilocytosis. The sufficient number of leukocytes, neutrophilia, atypical lymphocytes. Platelet count decreased, evenly distributed, normal shape. Impression: Microcytic hypochromic anemia with anisopoikilocytosis accompanied by inflammation and thrombocytopenia. Suggestion Iron status, Hb electrophoresis if the iron status is normal, monitor CBC. Coomb Test: Direct negative, Indirect negative. Blood Type O.

Bloodchemistry: Glucose as 92 mg/dL, Albumin 3.0 g/dL; Fe 41 g/dL, TIBC 164 g/dL. SGOT 76 mg/dL; SGPT 15 mg/dL, Total Bilirubin 0.8 mg/dL, Direct Bilirubin 0.5 mg/dL, Indirect Bilirubin 0.3 mg/dL, Ferritin >40,000 ng/mL, Rheumatoid factor non reactive, Calcium 7.6 mg/dL, Sodium 134 mEq/dL, Potassium 3.4 mEq/dL, Urea 15 mg/dL, Creatinine 0.44 mg/dL. Uric acid 2.1 mg/dL.

Urinalysis (16/10/2019)

Yellow color, clear, BJ 1.010, pH 7.0, negative protein, negative glucose, negative ketones, negative blood, negative bilirubin, urobilinogen 1, negative

nitrite, negative leukocyte esterase, urine sediment: epithelium negative, leukocytes 0-2 /LPB, erythrocytes 0-1, negative cylinder, negative crystals, positive bacteria, negative mucus, negative fungi.

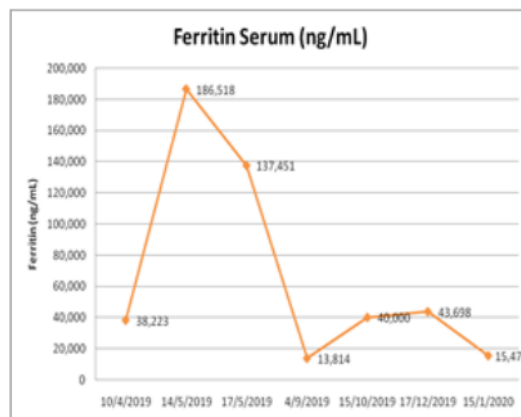
ANA test (15/4/2019): Negative.

Then it was repeated on 22/10/2019 and got the ANA test: speckled pattern, titer 1/100. Anti-ds DNA 81.13 IU/mL, ACA IgG 12.67 MPL and ACA IgG 15.19 MPL. CEA 3 ng/mL, CA 125 26.6 U/mL, and CA 15-3 25.9 U/mL. Complement test (30/10/2019): C3 261 mg/dL, and C4 62.6 mg/dL

ANA Profile: negative

Laboratory examination (22/10/2019) Routine blood, Hb 9.9 g/dL; erythrocytes 3.78 million/mm<sup>3</sup>; leukocytes 12,460/mm<sup>3</sup>; Ht 30%; platelets 129,000/ $\mu$ L. LDH 2160U/L. HBsAg negative, Anti HCV negative, Anti HIV negative. Total cholesterol 331 mg/dL, HDL 29 mg/dL, LDL 231 mg/dL, triglycerides 346 mg/dL. Thyroid function: T3 0.47 ng/mL, ft4 1.02 ng/mL, TSH 0.709 IU/mL.

Hb Electrophoresis (22/10/2019): HbF 0%, HbA2 2.7%, HbA 97.3%, GDT Hypochromic microcytic anemia with anisopoikilocytosis, no inclusion bodies found. Iron status: iron deficiency. HbA2 within normal limits, HbF was not detected. Impression: Hb electrophoresis within normal limits, the hemolytic process can not be ruled out.



Consul for clinical oncology hematology division.

Impression: anemia of chronic disease with hyperferritinemia. Suggestions: transfusion PRC, observation of iron status and management of inflammatory conditions, BMP.

BMP (4/11/2019): Normal

Consul for infectious and tropical divisions

Impression: a chronic infection such as bacteria and fungi still cannot be ruled out.

Suggestion: look for foci of infection, culture, and resistance of bacteria and fungi.

Culture and resistance of microorganisms (10/25/2019) negative urine material. Blood material, the name of the bacteria *Staphylococcus hominis* ssp *hominis*, microscopic results of the suspect colony gram (+) coccus (+), the name of the antibiotic Tigecycline, interpretation: sensitive, MIC 0.25.

Fungal Culture and Resistance (25/10/2019)  
Fungal Culture and Resistance (25/10/2019) blood and urine materials, negative results. Pharyngeal swab material, the name of the fungus *Candida albicans*, microscopic results of KOH yeast cell (+).

Serological examination.

Toxoplasma and Rubella IgG/IgM non-reactive.

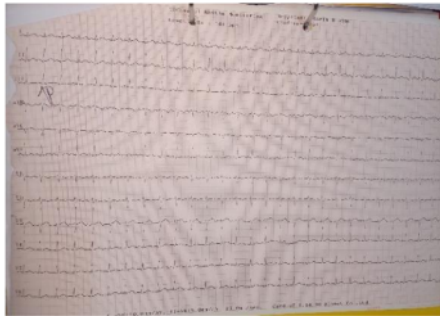
CMV IgG/IgM: 178 (†)/0.07(N).

Widal S. Typhi O 1/80, H 1/80.

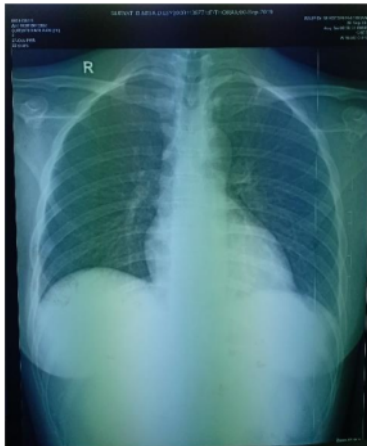
Feces examination (30/10/2019)

Macroscopic: Brownish yellow color, soft consistency.

Microscopy: negative amoeba, erythrocyte 0-1/Lp, leukocyte 0-1/Lp, negative fungus, negative worm eggs, fat food residue negative, negative occult blood.

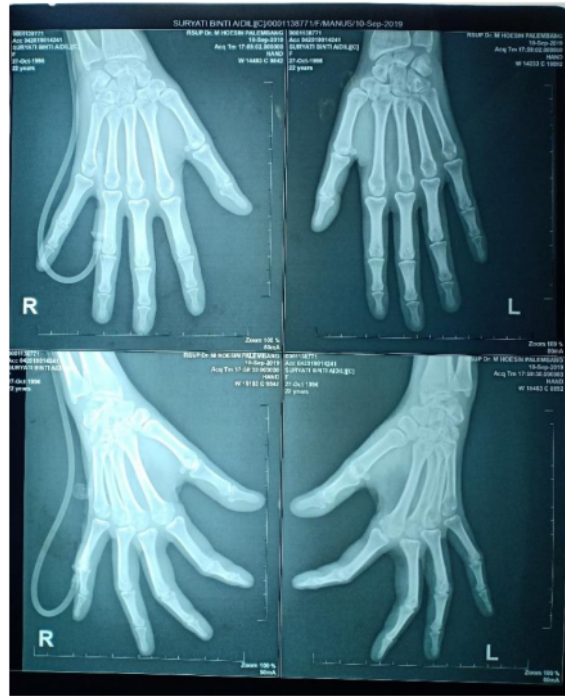

ECG (31/10/2019). Impression: sinus tachycardia.

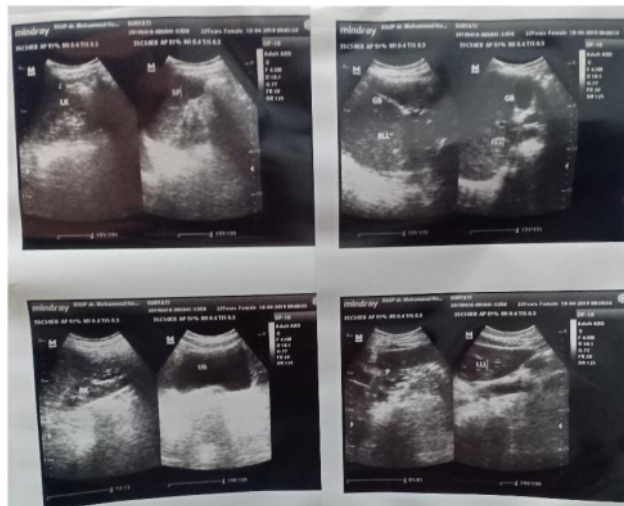

Chest X-thorax PA (09/06/2019)

Impression: normal.



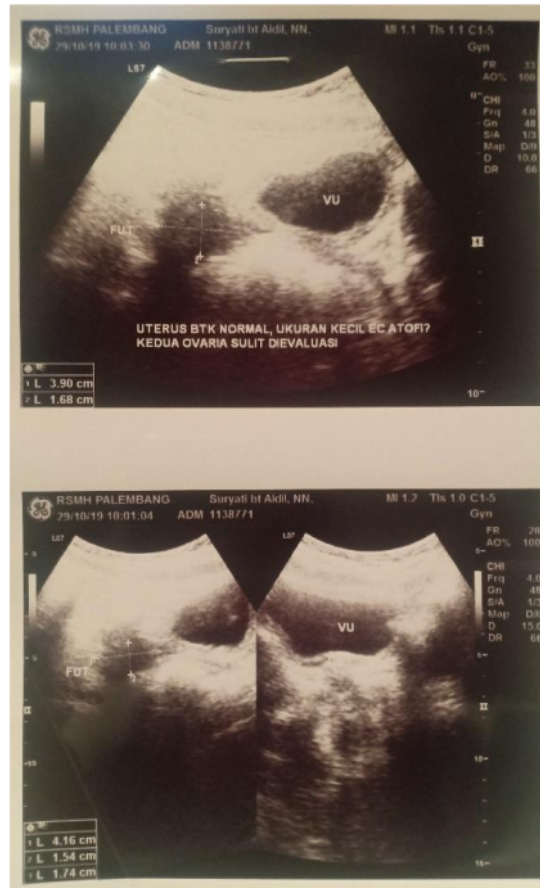X-ray of the AP/Oblique right dextra sinistra (27/10/2019). Impression: no radiological abnormalities were seen on bilateral



Ultrasound Abdomen (18/4/2019) Impression: Normal.

Laboratory (7/11/2019) function of female hormones LH 23.34 mIU/mL, FSH 67.43, estradiol 46 pg/mL.





Gynecological ultrasound (29/10/2019)

AF uterus is normal in shape and shrinks in size by 3.9 cm x 1.68 cm. Homogeneous myometrium, regular stratum basalis. Both ovaries are difficult to evaluate. Conclusion the uterus shrinks ec. Suspected atrophy; Both ovaries are difficult to evaluate.

Consul for Obstetrics and Gynecology.  
 Impression: amenorrhea Secondary. drug-induced.  
 Suggestion: Treatment of basic disease according to Internal Medicine TS and re-evaluation after methylprednisolone therapy is completed.

Dental and Oral Consul:

Sides ~~765~~ 4  
 78

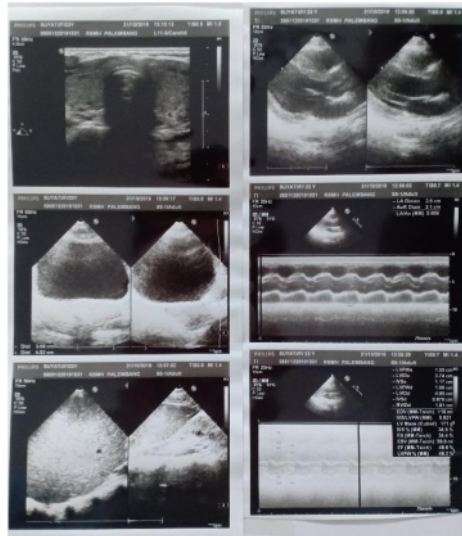
Impression: Pulpitis  
 Suggestion: Pro tumpatan

Sides ~~1~~ 12

Impression: Fracture 2/3 crown  
 Suggestion: Pro extraction

Consul for Eyes:

Impression: Vasculitis (-), Refractive error  
 Suggestion: Consultation to the refractive



Unit Echocardiography (31/10/2019)

Wall motion, good chamber, good valve, 60% EF.

Impression: normal.

Consul for cardiovascular division.

Impression: Pericardial effusion is absent.

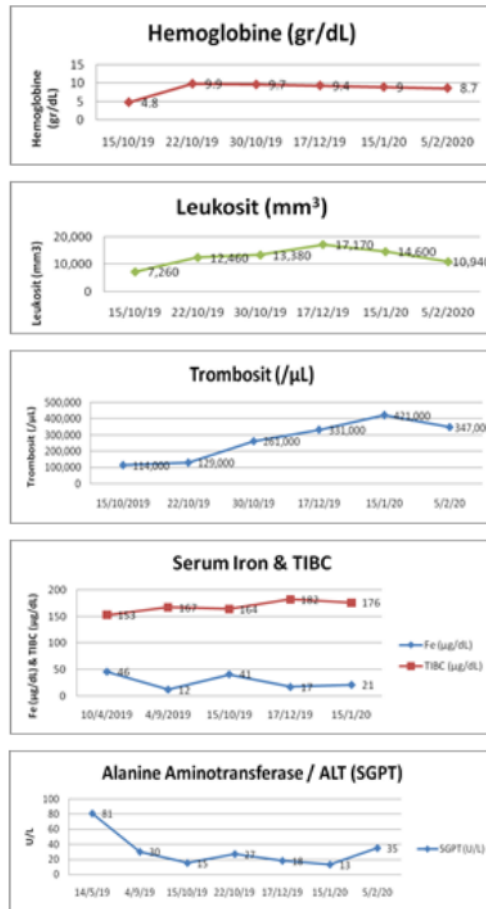
Suggestion: Evaluate the cause of hypermetabolic.

Based on Yamaguchi's 1992 criteria (meets 5 criteria, with at least 2 major criteria being met) 4 major criteria were obtained, namely fever 39°C for more than 1 week, arthralgia 2 weeks, red spots/rash, and leukocytosis 10,000/mm<sup>3</sup> with 80% PMN. Minor criteria 1 met namely abnormal liver function tests. Exclusion criteria were infection, malignancy, and rheumatic disease, especially vasculitis. Based on the Fautrel 2002 criteria, 3 major criteria were met, namely fever, arthralgia, neutrophilia 80% and the minor criteria were met, namely maculopapular rash and leukocytosis ≥10,000/mm<sup>3</sup>.<sup>1</sup>

The patient is currently diagnosed with Adult-Onset Still's Disease (AOSD) with dyslipidemia and secondary amenorrhea. Patients can still be differentially diagnosed with Systemic Lupus Erythematosus with hyperferritinemia, and a malignancy still needs to be observed during therapy. During treatment at RSMH, the patient was treated

with 4 mg methylprednisolone tablets (4-3-2 tab/day), accompanied by a transfusion of 1000 cc PRC gradually, then after the anemia was resolved, methotrexate 10 mg per week was started along with folic acid 5 mg per week. Paracetamol 500 mg 8 hours (prn), CaCO<sub>3</sub> tablets 500 mg 8 hours, Omeprazole capsules 20 mg 24 hours, Simvastatin 20 mg 24 hours. The patient was given the antibiotic Ceftriaxone 1 gram per 12 hours for 5 days and continued with antibiotics based on the culture results, Tigecycline 50 mg per 12 hours and Candistatin drop 1 cc per 6 hours based on the results of the pharyngeal swab culture obtained. The patient went home with clinical improvement.

Patients routinely carry out outpatient control at the polyclinic rheumatology once a month. On December 17, 2019, and January 15, 2020, complaints of fever and joint pain in the wrists, knees, and fingers decreased. Physical examination revealed vital signs within normal limits and a body weight of 49 kg. Specific conditions: pale palpebral conjunctiva (-/-), periorbital hyperpigmentation (+). Nose, mouth, and neck within normal limits. Cor and pulmo within normal limits. Abdomen and extremities within normal limits. KGB no magnification.



Monitoring progress and side effects of the therapy continues to be carried out on patients including clinical examination, hematological support, and liver function. The patient was treated with methotrexate 10 mg per week, folic acid 5 mg per week, methylprednisolone 4 mg per 12 hours (dose after tapering and continued maintenance), paracetamol 500 mg every 8 hours (prn), CaCO3 tablets 500 mg every 8 hours, Omeprazole capsules 20 mg 24 hours (prn), Simvastatin 10 mg 24 hours.

### 3. Discussion

Patients diagnosed with Adult-Onset Still's Disease (AOSD) with dyslipidemia and secondary

amenorrh<sup>10</sup>ea. AOSD is a rare, immune-mediated, multisystem inflammatory disorder characterized by high fever, skin rash, and arthritis. These cases often go undiagnosed and one of the main reasons for hospitalization is due to fever of unknown cause. The diagnosis of AOSD was made based on the Yamaguchi 1992 criteria, which met 5 criteria, with at least 2 major criteria being met. The major criteria were fever 39°C for more than 1 week, arthralgia 2 weeks, red patches/rash, and leukocytosis 10,000/mm<sup>3</sup> with 80% PMN. Minor criteria were sore throat, lymphadenopathy, hepatomegaly or splenomegaly, abnormal liver function, negative ANA, and RF tests. Exclusion criteria were infection,

malignancy (especially malignant lymphoma), and other rheumatic diseases (especially systemic vasculitis). met, namely abnormal liver function tests. In this patient, 4 major criteria were met, namely fever 39°C for more than 1 week, arthralgia 2 weeks, red patches/rash, and leukocytosis 10,000/mm<sup>3</sup> with ≥80% PMN. Minor criteria 1 met namely abnormal liver function tests. Exclusion criteria were infection, malignancy, and other rheumatic diseases after observation and therapy were considered not met in this patient.<sup>1</sup>

Based on the 2002 Fautrel criteria must meet 4 or more major criteria or 3 major criteria plus 2 minor criteria. Major criteria include high fever 39°C, arthralgia, transient erythema, pharyngitis, PMN≥80%, and ferritin glycosylated 20%. Minor criteria include a maculopapular rash and leukocytosis 10,000/mm<sup>3</sup>. In this patient, 3 major criteria were met, namely high fever 39°C, arthralgia, neutrophilia ≥80%, and the minor criteria were met, namely maculopapular rash and leukocytosis 10,000/mm<sup>3</sup>.

Yamaguchi criteria have a sensitivity of 78.57% and an accuracy of 87.14%. The Fautrel classification has a sensitivity of 80.6% and a specificity of 98.5%. Currently, most of the studies on AOSD use Yamaguchi and/or Fautrel criteria.<sup>1</sup>

For the diagnosis of SLE in this patient, clinical manifestations of skin and non-erosive arthritis were found, whereas, in the laboratory, both the 1997 ACR and SLICC 2012 criteria were not met. ACR 2019 diagnosis of SLE in this patient is still possible, namely a history of a positive ANA-IF titer 1:80 (or positive with other examination methods equivalent) is required to include the patient in the SLE classification. Clinically, the eligible constitutional domain is fever (score 2), the arthritis domain has at least 2 joint pains (score 6), the skin domain has cutaneous lupus (score 4), and the patient does not have immunological domain criteria, so the total score is 12. The patient met the SLE classification if the total score was 10 with at least one meeting the

clinical criteria.<sup>5,6</sup>

Hyperferritinemia in this patient was found to be very high. Although hyperferritinemia is non-specific, it may be diagnostically very contributing if properly interpreted. Ferritin is a protein synthesized by the liver and plays a role in iron storage in the liver, macrophages, and erythrocytes. Increased ferritinemia does not necessarily mean iron overload or liver disease. In AOSD cases there is an increase in serum ferritin levels, usually five times, or more, above the normal range, which can sometimes reach extreme values (>50,000 g/dL). Although not necessarily disease-specific, serum hyperferritinemia is often used to aid in the diagnosis of AOSD and serial serum levels are often used as a kind of biomarker to monitor response to treatment.<sup>7,8,9</sup>

Complementary DNA (antioxidant responsive element/Maf recognition element) along with mRNA (iron-responsive element) regulates the rate of ferritin synthesis. Cytoplasmic ferritin content is regulated by ferritin mRNA translation in response to the intracellular pooling of "chelatable" and "labile" iron. Inflammation is also associated with increased ferritin production by the histiocyte macrophage system and/or increased release from damaged hepatocytes. However, the precise mechanism and regulation of this phenomenon are still not clearly understood. Ferritin levels increase in several autoimmune diseases such as RA but rarely reach as high as in AOSD.<sup>10</sup> Likewise, serum ferritin can be significantly increased in SLE patients, especially in severe SLE activity with hematological manifestations

The patient had a history of regular menstruation before the illness. Amenorrhea is a condition that refers to women who are unable to menstruate. This situation can occur when a woman is 16 years old but has not had a menstrual period, or what is commonly called primary amenorrhea, or secondary amenorrhea, which is when a woman of childbearing age who is not pregnant does not get her period again after 6 months from her last menstrual period. The patient was consulted to the obstetrics and

gynecology polyclinic and evaluated as secondary to drug-induced amenorrhea due to taking corticosteroid drugs.

The anti-inflammatory effect of corticosteroids cannot be separated from their metabolic effects through the same glucocorticoid receptor, therefore when corticosteroids are used in therapy, we must consider the side effects that will be caused. Side effects will increase according to the dose and duration of treatment so that the minimum dose needed to control the disease must be achieved.<sup>12</sup>

The hormones testosterone and estrogen, can be decreased with the administration of corticosteroids. Estrogen and testosterone play a role in the regulation of bone metabolism (hypogonadism in both men and women is associated with osteoporosis) and are factors in the development of corticosteroid-induced osteoporosis. Menstrual irregularities and amenorrhea may also result from glucocorticoid administration.<sup>12</sup>

Corticosteroids are effective in controlling AOSD in approximately 65% of patients. Based on the retrospective case series, the initial dose can be given in the range of 0.5-1 mg/kg/day. Tapering usually begins after 6 weeks. Response to corticosteroids is often rapid within hours or days.<sup>1</sup>

Methotrexate remains the most widely used DMARD in AOSD, particularly as a co-administration of steroid drugs. In 1999, Fautrel et al. reported low-dose methotrexate (7.5–17.5 mg/week) in 26 patients taking steroids. Twenty-three (88%) patients achieved partial remission and 18 (69%) complete remission. Eleven patients (39%) discontinued corticosteroids, while the mean daily intake of prednisone was progressively reduced. Thus, methotrexate should be added to prednisone therapy to control disease or reduce cases of steroid dependence.<sup>1</sup>

Based on studies and case series, several modalities of therapeutic strategy for AOSD are corticosteroids as the first-line treatment to induce remission. Then, the administration of methotrexate can be given immediately to prevent the side effects

of using steroids. In cases of AOSD that does not respond to steroids and methotrexate, chronic arthritis can be treated with tocilizumab or infliximab while AOSD with systemic manifestations can be treated with anakinra. Further research is still needed to determine the effect of these various therapeutic modalities.<sup>1,14,15</sup>

#### 4. Conclusion

The diagnosis of autoinflammation can be made based on clinical features and supported by other investigations. Adult-Onset Still's Disease (AOSD) is a rare multisystemic autoinflammatory disorder with unknown etiology and difficult diagnosis due to various differential diagnoses that must be ruled out. AOSD therapy strategy is corticosteroids as the first line to induce remission and methotrexate can be given immediately to reduce the side effects of steroid use.

#### 5. References

1. Gerfaud-Valentin M, Jamilloux Y, Iwaz J. Adult-onset Still's disease. *Autoimmunity Reviews*. 2014; 13: 708-722 [cited January 2, 2020]. Available from: <http://dx.doi.org/10.1016/j.autrev.2014.01.058>
2. Cush JJ. Autoinflammatory Syndrome. 2013. *Dermatol Clin*. 2013 July; 31(3): 471–480 [cited January 1, 2020]. Available from: <https://www.ncbi.nlm.nih.gov/pmc/articles/PMC4489412/>
3. Eftimiou P, Moorthy LN, Mavragani CP, Skokos D, Fautrel B. Adult Onset Still's Disease and autoinflammation. *Hindawi Publishing Corporation International Journal of Inflammation*. June 2012. [cited January 1, 2020]. Available from: <http://downloads.hindawi.com/journals/specialissues/503921.pdf>

4. Mavragani CP, Spyridakis EG, Koutsilieris M. Adult-Onset Still's Disease: From Pathophysiology to Targeted Therapies. Hindawi Publishing Corporation International Journal of Inflammation. April 2012. [cited January 1, 2020]. Available from: <https://www.hindawi.com/journals/iji/2012/879020/>
5. Aringer M, Costenbader K, Daikh D, Brinks R, Mosca M, et.al. European League Against Rheumatism/American College of Rheumatology classification criteria for systemic lupus erythematosus. *Ann Rheum Dis.* 2019; 78: 1151–1159 [cited January 1, 2020]. Available from: <https://ard.bmj.com/content/78/9/1151.share>
6. Indonesian Rheumatology Association. Recommendations from the Indonesian Rheumatology Association: Diagnosis and Management of Systemic Lupus Erimatosus. Revised Edition of the Diagnosis and Management of Systemic Lupus Erimatosus 2011. Jakarta, 2019
7. Serraj K, Hamaz S, Alaloui H, Bachir H, Andrès E. Diagnosis of hyperferritinemia in 2019. *Integr Food Nutr Metab*, 2019; 6(1):1-4 [cited January 1, 2020]. Available from: <https://www.oatext.com/pdf/IFNM-6-241.pdf>
8. Kernan KF, Carcillo JA. Hyperferritinemia and inflammation. *International Immunology.* 29(9): 401–409 [cited January 1, 2020]. Available from: <https://www.ncbi.nlm.nih.gov/pmc/articles/PMC5890889/>
9. Rosário C, Goddard GZ, Holtz EGM, D'Cruz DP, Shoenfeld Y. The Hyperferritinemic Syndrome: macrophage activation syndrome, Still's disease, septic shock and catastrophic antiphospholipid syndrome. [cited January 3, 2020]. Available from: <http://www.biomedcentral.com/1741-7015/11/185>
10. Mehta B, Efthimiou P. Ferritin in Adult-Onset Still's Disease: Just a Useful Innocent Bystander?, *International Journal of Inflammation.* 2012 [cited January 1, 2020]. Available from: <https://www.semanticscholar.org/paper/Ferritin-in-Adult-Onset-Still's-Disease%3A-Just-a-Mehta-Efthimiou/2c6a264019d151177377981ee7f5fe9796395922>
11. Gamal NM, Khedr TM, Ismail NM, Ramadan H, Badawy ER. Is it useful to measure serum ferritin levels in systemic lupus erythematosus patients? *The Egyptian Rheumatologist.*[cited 1 January 2020]. Available from: <https://www.sciencedirect.com/science/article/pii/S1110116419300535>
12. Stanbury RM, Graham EM. Systemic corticosteroid therapy: side effects and their management. *British Journal of Ophthalmology*, June 1998. [cited 1 January 2020]. Available from: <https://bjo.bmj.com/content/bjophthalmol/82/6/704.full.pdf>
13. Yang JW, Lee E, Seo JY, Jung JY, Suh CH, Kim HA. Application of the international league against rheumatism classification criteria for systemic juvenile idiopathic arthritis as a prognostic factor in patients with adults-onset Still's disease. *Pediatric Rheumatology.* 2018; 16: 9.
14. Feuerstein JL, Klein DE, Mikhitarian MA, Mehta A. Quotidian High Spiking Fevers in Adult Still's Disease. *Am J Case Rep*, 2017; 18: 580-588.

15. Vollenbroek FTMB, Doggen CJM, Janssens RWA, Moens HJB. Dermatological guidelines for monitoring methotrexate treatment reduce drug survival compared to rheumatological guidelines. PLOS ONE. March 23, 2018. Available from: <https://doi.org/10.1371/journal.pone.0194401>

# Indonesian Journal of Rheumatology

---

## ORIGINALITY REPORT

---

19%

SIMILARITY INDEX

13%

INTERNET SOURCES

15%

PUBLICATIONS

4%

STUDENT PAPERS

---

## PRIMARY SOURCES

---

1	<a href="http://www.ijopp.org">www.ijopp.org</a> Internet Source	1%
2	R. M STANBURY, E. M GRAHAM. "Systemic corticosteroid therapy---side effects and their management", British Journal of Ophthalmology, 1998 Publication	1%
3	<a href="http://www.tandfonline.com">www.tandfonline.com</a> Internet Source	1%
4	"Auto-Inflammatory Syndromes", Springer Science and Business Media LLC, 2019 Publication	1%
5	<a href="http://www.oatext.com">www.oatext.com</a> Internet Source	1%
6	Submitted to Postgraduate Institute of Medicine Student Paper	1%
7	"RHEUMATOID ARTHRITIS ? TREATMENT", APLAR Journal of Rheumatology, 8/2006 Publication	1%

---



8	"Abstracts from the 36th Annual Meeting of the Society of General Internal Medicine", Journal of General Internal Medicine, 2013 Publication	1 %
9	Pei-Dong Chen, Sheng-Lei Yu, Shu Chen, Xin-Hua Weng. "Retrospective study of 61 patients with adult-onset Still's disease admitted with fever of unknown origin in China", Clinical Rheumatology, 2011 Publication	1 %
10	<a href="http://www.bcpsbd.org">www.bcpsbd.org</a> Internet Source	1 %
11	<a href="http://coek.info">coek.info</a> Internet Source	1 %
12	Submitted to Udayana University Student Paper	<1 %
13	<a href="http://www.karger.com">www.karger.com</a> Internet Source	<1 %
14	<a href="http://iranianra.ir">iranianra.ir</a> Internet Source	<1 %
15	<a href="http://www.frontiersin.org">www.frontiersin.org</a> Internet Source	<1 %
16	<a href="http://internalmedicine.imedpub.com">internalmedicine.imedpub.com</a> Internet Source	<1 %
17	<a href="http://www.prep4usmle.com">www.prep4usmle.com</a> Internet Source	<1 %

<1 %

18

Alper Soylu, Yeşim Öztürk, Belde Kasap, Nilüfer Akman, Mehmet Türkmen, Salih Kavukçu. "Clinical quiz: A pediatric case presenting with fever and diffuse myalgia", *Rheumatology International*, 2004

Publication

<1 %

19

Tomoko Sugiura. *Arthritis Research & Therapy*, 2006

Publication

<1 %

20

[journals.lww.com](http://journals.lww.com)

Internet Source

<1 %

21

[www.researchgate.net](http://www.researchgate.net)

Internet Source

<1 %

22

Weng Seng Fong, Nai Lee Lui. "Adult-Onset Still's Disease: A Review", *Proceedings of Singapore Healthcare*, 2013

Publication

<1 %

23

Yousra Ibn Yacoub. "Bilateral low lobar atelectasis in a young woman with adult-onset Still's disease", *Rheumatology International*, 08/29/2009

Publication

<1 %

24

"The Endocrine Society's 95th Annual Meeting and Expo, June 15–18, 2013 – San Francisco", *Endocrine Reviews*, 2013

<1 %

25

A. Dagan, M. Kogan, Y. Shoenfeld, G. Segal.  
"When uncommon and common coalesce:  
adult onset Still's disease associated with  
breast augmentation as part of autoimmune  
syndrome induced by adjuvants (ASIA)",  
Clinical Rheumatology, 2015

Publication

---

<1 %

26

Arun Agarwal, Aakanksha Agarwal, Abu Khan.  
"A Case of Adult Stills Disease: Not So  
Uncommon Cause of Fever of Unknown  
Origin", Asian Journal of Medicine and Health,  
2018

Publication

---

<1 %

27

doaj.org  
Internet Source

<1 %

---

28

Efthimiou, P.. "Pathogenesis and  
Management of Adult-Onset Still's Disease",  
Seminars in Arthritis and Rheumatism, 200612

Publication

---

<1 %

29

Pasini, J.. "Disseminated ureteral carcinoma  
discovered in a woman patient at childbirth",  
European Journal of Obstetrics and  
Gynecology, 20050801

Publication

---

<1 %

30

Submitted to University of Hertfordshire  
Student Paper

<1 %

---

31	<a href="https://fjfsdata01prod.blob.core.windows.net">fjfsdata01prod.blob.core.windows.net</a> Internet Source	<1 %
32	<a href="http://www.mdpi.com">www.mdpi.com</a> Internet Source	<1 %
33	<a href="http://www.mims.com.vn">www.mims.com.vn</a> Internet Source	<1 %
34	<a href="http://www.oalib.com">www.oalib.com</a> Internet Source	<1 %
35	Artha Falentin Putri Susilo, Kevin Dominique Tjandraprawira, Anita Rachmawati. "Isolated growth hormone deficiency and amenorrhea – Case report", <i>Annals of Medicine and Surgery</i> , 2022 Publication	<1 %
36	<a href="http://bioscmed.com">bioscmed.com</a> Internet Source	<1 %
37	Valentina Bagnari. "Adult-onset Still's disease", <i>Rheumatology International</i> , 12/18/2009 Publication	<1 %
38	<a href="http://www.hkmj.org">www.hkmj.org</a> Internet Source	<1 %
39	<a href="http://www.alliedacademies.org">www.alliedacademies.org</a> Internet Source	<1 %
40	<a href="http://www.cureus.com">www.cureus.com</a> Internet Source	<1 %

41	<a href="http://www.dovepress.com">www.dovepress.com</a> Internet Source	<1 %
42	<a href="http://www.heighpubs.org">www.heighpubs.org</a> Internet Source	<1 %
43	Huey-Liang Kuo, Chun-Liang Lin, Chiu-Ching Huang. "Reversible Thick Ascending Limb Dysfunction and Aseptic Meningitis Syndrome: Early Manifestation in Two Leptospirosis Patients", Renal Failure, 2009 Publication	<1 %
44	<a href="http://bmcmmedicine.biomedcentral.com">bmcmmedicine.biomedcentral.com</a> Internet Source	<1 %
45	<a href="http://www.spandidos-publications.com">www.spandidos-publications.com</a> Internet Source	<1 %
46	"EAPCCT Abstracts", Clinical Toxicology, 2008 Publication	<1 %
47	F. Ciccarelli, M. Martinis, L. Ginaldi. "An Update on Autoinflammatory Diseases", Current Medicinal Chemistry, 2013 Publication	<1 %
48	<a href="http://www.wjgnet.com">www.wjgnet.com</a> Internet Source	<1 %

# Indonesian Journal of Rheumatology

---

## GRADEMARK REPORT

---

FINAL GRADE

**/0**

GENERAL COMMENTS

**Instructor**

---

PAGE 1

---

PAGE 2

---

PAGE 3

---

PAGE 4

---

PAGE 5

---

PAGE 6

---

PAGE 7

---

PAGE 8

---

PAGE 9

---

PAGE 10

---

PAGE 11

---

PAGE 12

---

PAGE 13

---

PAGE 14

---