

# Slow Response to Anti-tuberculosis Drug in a 12-year Old Girl: Is it Multi Drug Resistant Tuberculosis or Paradoxical Response?

Heda Melinda\*, Minerva Kadir

Department of Child Health Faculty of Medicine Universitas Padjadjaran, Bandung, Indonesia

\*Corresponding author: [heda\\_1155@yahoo.com](mailto:heda_1155@yahoo.com)

Received September 05, 2015; Revised September 09, 2015; Accepted September 18, 2015

**Abstract** Clinical deterioration during treated with anti-tuberculosis drug (ATD) is not common occurred in immunocompetent children, remains a great dilemma. It requires medical attention, practitioners should be considered as multi-drug resistant tuberculosis (MDR-TB) or paradoxical response. We report a challenging case of a-12-year-old girl presented with clinical deterioration severe respiratory distress transferred to isolated pediatric intensive care unit while on TB treatment. On admission, chest X-ray revealed pneumothorax in left lung and bilateral pulmonary infiltration. During evaluation, she had seizure and decreased consciousness, and later diagnosed as as tuberculous meningitis (TBM). She had close contact with her acid-fast bacillus (AFB)-positive, Gene Xpert MTB/RIF negative-mother. Five other siblings were diagnosed as having TB as well. The patient was first suspected as having MDR-TB, while Gene Xpert MTB/RIF test revealed still positive. The patient then showed good clinical improvement after TB treatment.

**Keywords:** tuberculosis, MDR-TB, paradoxical response, Gene Xpert MTB/RIF

**Cite This Article:** Heda Melinda, and Minerva Kadir, "Slow Response to Anti-tuberculosis Drug in a 12-year Old Girl: Is it Multi Drug Resistant Tuberculosis or Paradoxical Response?" *American Journal of Medical Case Reports*, vol. 3, no. 10 (2015): 344-346. doi: 10.12691/ajmcr-3-10-10.

## 1. Introduction

Tuberculosis (TB) in children can evolve to severe forms and advanced disease requiring mechanical ventilation of the patients [1],

Worsening condition of TB under therapy should be carefully handled by health practitioners. This condition develops due to several conditions, such as multi-drug resistant tuberculosis (MDR-TB), slow response anti-tuberculosis drug (ATD) therapy associated with immunocompromised status, malnutrition, poor compliance, poor drug absorption. Paradoxical response have to be considered as the source after all possible condition has been excluded [2,3,4,5].

The paradoxical response phenomenon is defined as the worsening clinically or radiologically during initiation of ATD therapy, related to temporally recovery of the immune system. [6] A paradoxical response has been reported occur in 5–35% of cases, mostly in immunocompromised patients such as those with HIV [7,8].

The paradoxical phenomenon generally occurs ranging from 20 to 109 days in HIV-negative patients, dominantly involve central nervous system (CNS) and respiratory system [6,8].

## 2. Case Presentation

We report a-12-year-old girl with critically respiratory distress came to our emergency department (ED) as a

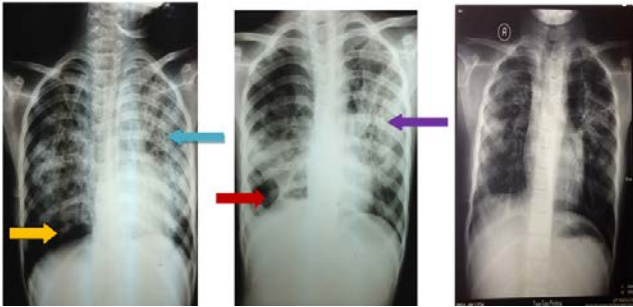
referral from secondary hospital. In the past two months, she had been treated for pulmonary tuberculosis (TB) due to prolonged cough and loss of weight by local community health centre. She was given intensive phase fixed drug combination (FDC) with appropriate dose and good adherence.

She lives together with other 8 residents in a crowded house. Her mother was thought to be adult-source contact with acid-fast bacillus (AFB)-positive, was on TB therapy, as well as her 6 other siblings. Her youngest sister was diagnosed as having tuberculous meningitis, and shunt was inserted due to hydrocephalus. There was no history of Bacillus Calmette Guerin (BCG) vaccination in all of the family members.

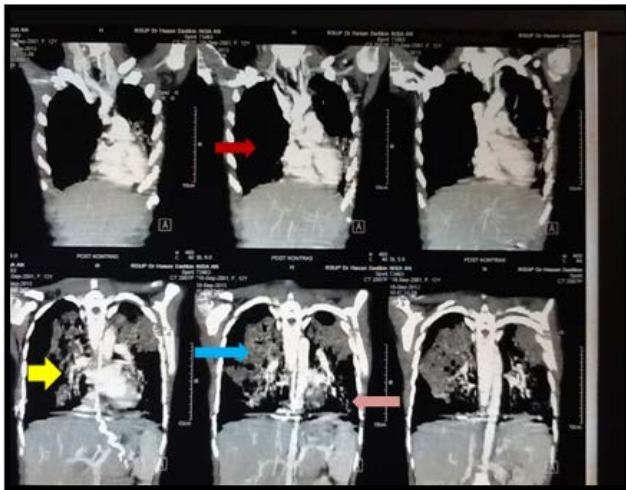
Physical examination on admission appeared severely ill with profound respiratory distress. Anthropometric data showed severe malnutrition. On the 4<sup>th</sup> day general seizure occurred for 5 minutes, after seizure she was somnolent, with positive meningeal sign, hyperreflexia, and presenting pathological reflex.

Laboratory test showed mild anemia, leukocytosis. Three consecutive AFB smear from gastric aspirate at the initial evaluation were found one positive and two negative. Chest X-ray revealed hydropneumothorax (yellow arrow), atelectasis and bilateral infiltration (blue arrow) (Figure 1A). During hospitalization, chest tube was inserted and showed improvement, inflated lung (purple arrow) and reduce pneumothorax (red arrow) (Figure 1B) then confirmed by Thoracic CT-Scan (Figure 2). A

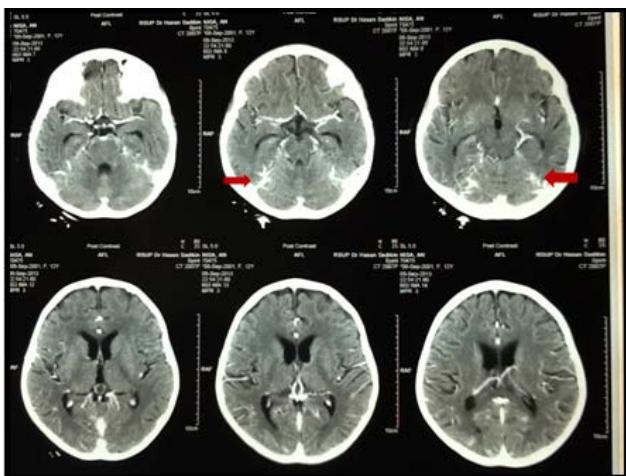
continuous suction was then inserted and she was admitted to isolated pediatric intensive-care unit (PICU). Lumbar puncture during hospitalization, showed mononuclear dominated pleiocytois, elevated protein, and cerebrospinal fluid to serum glucose ratio  $<0.5$ . From head CT-Scan we found meningeal enhancement. (Figure 3).



**Figure 1.** A. Initial chest X-ray. Right hydropneumothorax and bilateral infiltrat in all entire lungs, continuous suction was inserted. B. After removal of continuous suction, re-expanded lung, small trapped pneumothorax in right inferior lung lobe were demonstrated. C. Follow up



**Figure 2.** Thoracic CT-Scan without contrast showed pneumothorax (red arrow), Collapsed lung (yellow arrow), Multiple cystic formation (blue arrow), Bronchiectasis (pink arrow)



**Figure 3.** Head CT Scan with contrast showed the lesion by the red arrow

The result of Gene Xpert MTB/RIF examination detected rifampicin sensitive *Mycobacterium tuberculosis*. examination reveals rifampicin-sensitive. We also

evaluated for a possibility of Human Immunodeficiency Virus (HIV) infection with negative result.

She was then diagnosed tuberculous meningitis (TBM). Ethambutol 20 mg/kgBW and prednison 2 mg/kgBW were added in addition to previous treatment with INH 10 mg/kgBW, RIF 15 mg/kgBW, PZA 35 mg/kgBW, antimicrobial as well for the purposed secondary infection.

She was discharged of hospitalization with good condition. No respiratory distress, no fever, no cough and she had gained four kilograms in the past 3 month.

### 3. Discussion

Severe manifestation during TB therapy in immunocompetent adolescent occasionally happened. As reported by Cruz, et al [9] in Houston, adolescents aged range under 18 years came to emergency department most commonly with seizure and altered mental status.

Severe respiratory distress and altered mental status could be major causes of patient admitted to intensive care and contributed as poor prognosis [6,10] In this case, patient was referred with profound respiratory distress and should be isolated in pediatric intensive care unit.

Worsening of the TB clinical manifestation during treatment should be investigated due to secondary infections, inadequate ATD therapy, poor compliance, poor drug absorption, MDR-TB and paradoxical response as well [4,11,12].

In this patient we gave cephalosporin which has broad spectrum effects for possible secondary infection, other than TB infection [13].

It was difficult to assess children with MDR-TB while specimens suitable for culture and drug sensitivity test (DST) are more difficult to obtain. [14,15] Drug resistant TB should be suspected in children with bacteriologically proven TB who are not responding to the first-line drugs given with direct observation [16]. Gene Xpert MTB/RIF examination had been done to this patient and revealed still sensitive to rifampicin Found in South Africa by Nicol, et al Gene Xpert had rifampicin sensitivity 99,1% [17]. Repeated culture and smear with negative result in a patient with clinical and radiographical deterioration may indicate that the patient has other causes in addition to MDR-TB [16,18].

Paradoxical response should be considered as differential diagnosis of MDR-TB, as other causes had been excluded. Paradoxical response dominantly happened in extrapulmonary and disseminated TB, like miliary TB and TBM [19]. Previously, our patient was in well condition after being treated 2 months with ATD as dosage recommended by Graham's recent finding [20], but then she experienced severe respiratory distress.

Median regression time of paradoxical response of 46 days, ranging from 14 to 120 days, 63 days for CNS involvement and 56 days for other sites involvement. [6,19] Other factor that strengthened the possibility of paradoxical response was no history of BCG vaccination. Olive, et al [19] found children who suffered paradoxical response were never vaccinated with BCG. Vaccination supposed to offering a protection against this complication.

There is no specific treatment for paradoxical response. Optimal and watchful evaluation continuing with the same anti-TB treatment and if relevant, initiating corticosteroid

therapy. The total duration of ATD treatment was not influenced by the development of paradoxical responses [19,21,22]. In this patient, because of signs and symptoms of MTB, we added ethambutol and oral corticosteroid to the regimen while continuing the previous drugs. Oral corticosteroid in this case also effective for paradoxical response to regulate immune system [7],

Prognostic factor depends on manifestation occurred. TB meningitis stage III with deep decreasing consciousness had worse outcome, associated with seizure, needed surgery, delayed diagnosis and treatment [23]. Immediate awareness of paradoxical phenomenon avoids unnecessary changes in TB treatment

## 4. Conclusion

Tuberculosis can be progressively turn to respiratory distress. Paradoxical response of ATD should be considered as other causes in addition to drug-resistant TB while deteriorating the clinical manifestation. Recognition of this phenomenon will improve the outcome.

## Funding

None.

## Conflict of Interest

None.

## Acknowledgement

The authors thank to Harry Galuh radiologist, Rama Nusjirwan thoracic surgeon, Cissy Kartasasmita, Adi Utomo Suardi, Sri Sudarwati, Diah Asri Wulandari for the contribution of treating this patient well, and also the parents of the patient for permitting us to publish the case of their daughter.

## References

- [1] Silva DR, Gazzana MB, Dalcin TR. Severe tuberculosis requiring ICU admission. *J Bras Pneumol*. 2012;38(3):386-94.
- [2] Marais BJ. Childhood tuberculosis: epidemiology and natural history of disease. *Indian J Pediatr*. 2011;78:321-27.
- [3] Pinon I, Scolfaro C, Bignamini E, et al. Two pediatric cases of multidrug-resistant tuberculosis treated with linezolid and moxifloxacin. *Pediatr*. 2010;126:1253-56.
- [4] Ramachandran G, Kumar AK, Bhavani PK, et al. Age, nutritional status and INH acetylase status affect pharmacokinetics of anti-tuberculosis drugs in children. *Int J Tuberc Lung Dis*. 2013;17(6):800-6.
- [5] Shah I, Borse S. Paradoxical tuberculomas after completion of antituberculous treatment. *Trop Med Health*. 2012;40(1):15-7.
- [6] Cheng VCC, Ho PL, Lee RA, et al. Clinical spectrum of paradoxical deterioration during antituberculosis therapy in non HIV infected patients. *Eur J Clin Microbiol Infect Dis*. 2002;21:803-9.
- [7] Park JA, Park SS, Park SE. A paradoxical reaction during antituberculosis therapy for congenital tuberculosis. *Int J Infect Dis*. 2009;13:279-81.
- [8] Cheng VCC, Yam WC, Woo PCY, et al. Risk factors for development of paradoxical response during antituberculosis therapy in HIV-negative patients. *Eur J Clin Microbiol Infect Dis*. 2003;22:597-602.
- [9] Cruz AT, Hwang KM, Birnbaum GD, et al. Adolescents With Tuberculosis A review of 145 cases. *Pediatr Infect Dis J* 2013;32:937-41.
- [10] Valade S, Raskine L, Aout M, et al. Tuberculosis in the intensive care unit: A retrospective descriptive cohort study with determination of a predictive fatality score. *Can J Infect Dis Med Microbiol* 2012;23(4):173-78.
- [11] Cheng VC, Ho PL, Lee RA, Chan KS, Chan KK, Woo PC, Lau SK, Yuen KY. Clinical spectrum of paradoxical deterioration during antituberculosis therapy in non-HIV-infected patients. *Eur J Clin Microbiol Infect Dis*. 2002;21(11):803-9.
- [12] Park JA, Park SS, Park SE. A paradoxical reaction during antituberculosis therapy for congenital tuberculosis. *Int J Infect Dis* 2009;13:279-81.
- [13] Gray D, Zar HJ. Childhood pneumonia in low and middle income countries: burden, prevention and management. *Open Infect Dis J*. 2010;4:74-84.
- [14] Avdeeva T, Otvagin I, Myakisheva T, et al. Tuberculosis in adolescents and young patients in high prevalence region. *Eur J Microbiol Immunol*. 2012;4:297-301.
- [15] Berti E, Galli L, Venturini E, et al. Tuberculosis in childhood: a systematic review of national and international guidelines. *BMC Infect Dis*. 2014;4:1-10.
- [16] Marx G, Chan ED. Tuberculous meningitis: diagnosis and treatment overview. *Hindawi* 2011:1-10.
- [17] Nicol MP, Workman L, Isaacs W, et al. Accuracy of the Xpert MTB/RIF test for the diagnosis of pulmonary tuberculosis in children admitted to hospital in Cape Town, South Africa: a descriptive study. *Lancet Infect Dis*. 2011; 11: 819-24.
- [18] Perez-Velez CM, Marais BJ. Current concepts tuberculosis in children. *N Engl J Med*. 2012;367:348-61.
- [19] Olive C, Mouchet F, Toppet V, et al. Paradoxical reaction during tuberculosis treatment in immunocompetent children: Clinical spectrum and risk factors. *Pediatr Infect Dis J*. 2013;32:446-49.
- [20] Graham SM. Treatment of paediatric TB: revised WHO guidelines. *Paed Resp Rev*. 2011;12:22-6.
- [21] Hawkey CR, Yap T, Pereira J, et al. Characterization and management of paradoxical upgrading reactions in HIV-uninfected patients with lymph node tuberculosis. *Clin Infect Dis*. 2005;40:1368-71.
- [22] Ali U, Chikar S, Patil M, et al. Acute respiratory distress during paradoxical reaction to antituberculosis therapy in an 8 month old child. *Lung India*. 2012;29:381-3.
- [23] Nicolette NB, Jo W, Muloiwa R, et al. Presentation and outcome of tuberculous meningitis among children: experiences from a tertiary children's hospital. *Afr Health Sci*. 2014;14(1):143-9.