

P R O G R A M B O O K

40TH ANNUAL SCIENTIFIC MEETING

INDONESIAN
OPHTHALMOLOGIST
ASSOCIATION



13 - 15 AUGUST 2015
TRANS LUXURY HOTEL
BANDUNG

- FP04. *Author/s* Fitri Wisnuwardani, R. Angga Kartiwa
Affiliation Padjadjaran University
Abstract Title Karakteristik Demografi, Klinis dan Tajam Penglihatan Pasien dengan Benda Asing Intraokular
Presentation Time 09.00 - 09.10
- FP05. *Author/s* Kukuh Prasetyo, R. Angga Kartiwa
Affiliation Padjadjaran University
Abstract Title Visual Recovery after Penetrating Injury Through The Orbit
Presentation Time 09.10 - 09.20
- FP06. *Author/s* Sri Irmandha K.H.S. Muhiddin, Batari T.U., Djoko Widodo
Affiliation Hasanuddin University
Abstract Title Ocular Manifestations in Early Head Injury
Presentation Time 09.20 - 09.30
- FP07. *Author/s* Brian Arditya Mahendra, Marzarendra D. Erlangga, Purjanto Tepo Utomo
Affiliation Gadjah Mada University
Abstract Title Changes of Exophthalmos Degree and Intraocular Pressure after Therapy in Thyroid Associated Orbitopathy Patients at Dr. Sardjito General Hospital Yogyakarta
Presentation Time 09.30 - 09.40
- FP08. *Author/s* Reny Setyowati, Purjanto Tepo Utomo, Agus Supartoto
Affiliation Gadjah Mada University
Abstract Title Anterior Lamellar Repositioning for Management of The Upper Lid Entropion
Presentation Time 09.40 - 09.50
- FP09. *Author/s* Marzarendra D.E., Brian Arditya Mahendra, Purjanto Tepo Utomo
Affiliation Gadjah Mada University
Abstract Title Clinical Characteristic of Thyroid Associated Orbitopathy Patients at Dr. Sardjito General Hospital Yogyakarta
Presentation Time 09.50 - 10.00
- FP10. *Author/s* Shaelva Lassa Sabatini, Riani Erna
Affiliation Sriwijaya University
Abstract Title Treatment of Congenital Myogenic Ptosis with Frontalis Suspension Surgery
Presentation Time 10.30 - 10.40
- FP11. *Author/s* Merry Giovedi Eclipsia Yuniar, Sony Agung S.
Affiliation Brawijaya University
Abstract Title Hubungan antara Karakteristik, Gejala dan Tanda-tanda Graves Oftalmologi di RS Saiful Anwar Malang
Presentation Time 10.40 - 10.50
- FP12. *Author/s* Tri Winarti, Agus Supartoto
Affiliation Gadjah Mada University
Abstract Title Fine Needle Aspiration Biopsy in Choroidal Melanoma
Presentation Time 10.50 - 11.00
- FP13. *Author/s* Primery Putri, Ardizal Rahman
Affiliation Andalas University
Abstract Title The Case of Tumor Metastatic to the Orbit in Dr. M. Djamil Hospital Padang
Presentation Time 11.00 - 11.10



40TH ANNUAL SCIENTIFIC MEETING, BANDUNG 13 - 15 AUGUST 2015



CERTIFICATE
OF
ATTENDANCE

THIS IS TO CERTIFY THAT

RIANI ERNA, MD

HAS ATTENDED THE 40TH ANNUAL SCIENTIFIC MEETING AS
SPEAKER

Budiman, MD
Chairman



8e9304969277

Prof. DR. Nila F. Moeloek, MD
President of Indonesian Ophthalmologist Association

Accredited by Indonesian Medical Association (IDI) :
Symposium : No.244/SK/SP/IDI.WIL./JAB/VIII/2015, Speaker : 8 SKP, Moderator : 2 SKP, Participant : 10 SKP, Committee : 2 SKP
Course : No.245/SK/WS/IDI.WIL./JAB/VIII/2015, Speaker : 8 SKP, Participant : 12 SKP, Committee : 2 SKP

No. REG. PUBLIKASI DOSEN UPKK FAKULTAS KEDOKTERAN IINSRI	
TGL.	13-04-2016
No. REG.	0417309 B1 0502 -01030



TREATMENT OF CONGENITAL MYOGENIC PTOSIS WITH FRONTALIS SUSPENSION SURGERY

Shaelva Lassa Sabatini**, Riani Erna*
Ophthalmology Department, Medical Faculty of Sriwijaya University
Mohammad Hoesin Hospital Palembang

Introduction: Ptosis repair is a challenging oculoplastic surgical procedure that requires correct diagnosis, thoughtful planning, thorough understanding of eyelid anatomy, experience, and good surgical technique. Ptosis can cause functional problem and cosmetic issue.

Objective: To report 2 cases of congenital myogenic ptosis which were treated with frontalis suspension surgery.

Methods: Case report, a 11-year old and a 20-year old girl came to our clinic with chief complain drooping in the upper eyelid RE since their childhood. Patients also complained difficulty of reading. The degree of ptosis during the day was the same. No diplopia, dysphonia, dyspnea, and dysphagia. VA 20/20 in the both eyes. Ocular motility were normal. MRD₁ 0 mm, FP 5 mm, no upper eyelid crease, LF 4 mm, no lagophthalmos, eyelid lag present, upper eyelid RE higher than LE in down gaze, and Bells phenomenon normal. Light reflex of pupil positive and diameter 3 mm in standard room illumination. Schimer test and TBUT were within normal. We diagnosed these patients with congenital myogenic ptosis RE and performed frontalis suspension surgery with autogenous tensor fascia lata.

Result: Postoperative, for first patient we got MRD₁ 2 mm and FP 7 mm. For second patient we got MRD₁ 4 mm and FP 9 mm. Patients had no complain drooping in the upper eyelid RE and difficulty of reading anymore.

Conclusion: Frontalis suspension surgery is a way to treat patient with congenital myogenic ptosis who have poor levator function.

Keywords: congenital myogenic ptosis, frontalis suspension, autogenous tensor fascia lata

INTRODUCTION

Ptosis describe drooping or inferodisplacement of the upper eyelid. Ptosis is a common cause of reversible peripheral visual loss. Two classification systems are used to describe upper eyelid ptosis. It may be categorized by onset: congenital or acquired. Congenital ptosis is the most common form of ptosis that patients usually presents for treatment in worldwide. Ptosis may be classified by the cause: myogenic, aponeurotic, neurogenic, mechanical, or traumatic. The most common type of congenital ptosis results from a poorly developed levator muscle (myogenic cause).^{1,2,3,4}

Ptosis can cause functional problem and cosmetic issue. Many patients with ptosis complain of difficulty with reading because the ptosis worsens in down gaze. Ptosis that causes significant superior visual field loss or difficulty with reading is considered to be a functional problem, and correction of this defect often improves a patient's ability to perform the activities of daily living. In many instances,

ptosis is considered to be a cosmetic issue, causing a tired or sleepy appearance in the absence of a visual function deficit.¹

Ptosis repair is a challenging oculoplastic surgical procedure that requires correct diagnosis, thoughtful planning, thorough understanding of eyelid anatomy, experience, and good surgical technique. Levator function is the most important eyelid measurement in terms of surgical planning. Frontalis suspension surgery performed when levator function is poor or absent. When levator function is poor, the surgeon should consider utilizing the accessory elevators of the eyelid. Autogenous fascia lata graft is the gold standard for use in frontalis suspension surgery.^{1,2,4,5,6,7}

METHODS

This case report was conducted on 2 patients who came to Mohammad Hoesin Hospital Palembang at 2014. A 11-year old and a 20-year old girl complained drooping in the upper eyelid RE since their childhood. Patients

also complained difficulty of reading. The degree of ptosis during the day was the same. No diplopia, dysphonia, dyspnea, and dysphagia.

Ophthalmology examination were visual acuity (VA), ocular motility, margin reflex distance 1 (MRD₁), fissure palpebral (FP), upper eyelid crease, levator function (LF), the presence of lagophthalmos, the presence of eyelid lag, Bells phenomenon, and the examination of light reflex of pupil. Ancillary tests were tear film evaluation which were Schimer test and tear break-up time (TBUT).

VA 20/20 in the right and left eyes in both patients. Ocular motility were normal. In the right eye in both patients MRD₁ 0 mm, FP 5mm, no upper eyelid crease, LF 4 mm, no lagophthalmos, eyelid lag present, upper eyelid RE higher than LE in down gaze, and Bells phenomenon normal. Light reflex of pupil positive and diameter 3 mm in standard room illumination. Schimer test and TBUT were within normal. For first patient, MRD₁ in the left eye was 3 mm and for second patient, MRD₁ was 5 mm. We diagnosed these patients with congenital myogenic ptosis RE and performed frontalis suspension surgery with autogenous tensor fascia lata.

The postoperative results were considered as good if MRD₁ was 4.0 ± 0.5 mm (3.5-4.5 mm) and symmetry ≤ 1 mm; fair if MRD₁ was 2.5 ± 0.5 mm (2-3 mm) and symmetry 1.5 to 2.0 mm; and poor if MRD₁ was < 2 mm and symmetry < 2 mm.⁴

RESULT

Frontalis suspension surgery with autogenous tensor fascia lata was performed in 2 patients with congenital myogenic ptosis RE. After performed frontalis suspension surgery, for first patient we got MRD₁ 2 mm and FP 7 mm (Fig.1). For second patient we got MRD₁ 4 mm and FP 9 mm (Fig.2). Postoperative result was fair for first patient and good for second patient.

Patients had no complain drooping in the upper eyelid RE and difficulty of reading anymore. After performed frontalis suspension surgery, patients had lagophthalmos. But throughout follow up period of 6 months, lagophthalmos were resolved for both patients.

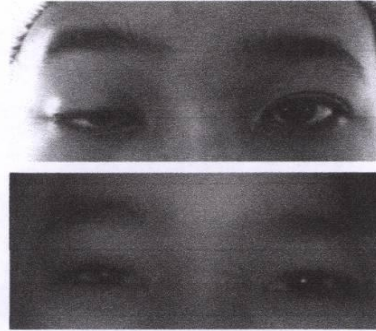

Fig 1. Top: Preoperative photograph of first patient. Bottom: Postoperative photograph of second patient with fair result.

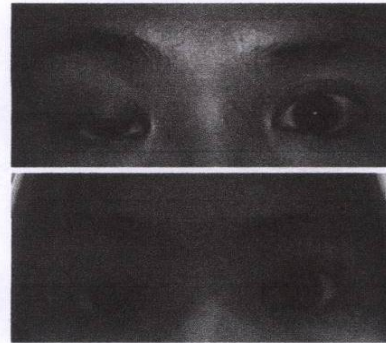


Fig 2. Top: Preoperative photograph of second patient. Bottom: Postoperative photograph of second patient with good result.

DISCUSSION

The results of this study demonstrate that frontalis suspension surgery was succeed for treating patients with congenital myogenic ptosis. Satisfactory surgical results were achieved 100% to both cases. Frontalis suspension surgery are the preferred repair procedures if levator function is poor or absent.^{1,2,4,5,6,7}

In this study, frontalis suspension surgery were done only in one eyes of each patients for unilateral ptosis. There is some controversy about whether bilateral frontalis suspension should be performed in patients with unilateral ptosis. Unilateral frontalis suspension surgery results in asymmetry in down gaze because of upper eyelid lag induced by the sling; in addition, there is less stimulus to elevate 1 brow. A bilateral procedure may improve the patient's symmetry, especially in downgaze, but it subjects the normal eyelid to surgical risks. The decision to modify a normal eyelid in an attempt to gain symmetry must be discussed by the surgeon and patient.¹

Lagophthalmos following ptosis repair is most common in patients with decreased levator function. But this condition is usually temporary. After performed frontalis suspension surgery, patients hadlagophthalmos. Lagophthalmos was treated with lubricating ointment. But throughout follow up period of 6 months, lagophthalmos were resolved for both patients.¹

The gold standard for use in frontalis suspension surgery is autogenous fascia lata graft. Previous study showed that the highest success rates were achieved by using autogenous fascia lata in frontalis suspension surgery. Autogenous fascia lata graft has shown the best long-term results but requires harvesting and additional surgery. Banked fascia lata may be obtained from a variety of sources. Various synthetic materials have been developed as an alternative for frontalis surgery. Wasserman BN, Sprunger DT, and Helveston EM compared various materials used in frontalis suspension surgery for incidence of infection and/or granuloma formation and incidence of recurrent ptosis. Of the materials compared in that study, autogenous fascia lata may be the material of choice for frontalis suspension surgery in congenital ptosis.^{1,4,7,8,9}

Synthetic materials such as silicone rods are commonly used. Silicone rod may improve eyelid elasticity, has little tissue reaction and allow easier adjustment or removal if necessary. Rizvi SA, Gupta Y, and Yousuf S evaluated the safety and efficacy of silicone rod in frontalis suspension surgery for severe congenital ptosis. Frontalis suspension surgery using silicone rod

was performed to 46 patients with severe congenital ptosis. The results were that its procedure is a safe and effective surgery, with few complications and easy removal and adjustment. Silicon rod can be an alternative beside the use of autogenous fascia lata graft because fascia lata is difficult to harvest, insufficient amounts to obtain, and can make post operativescarring at donor site.^{1,4}

Autogenous fascia lata was not suitable for younger patients because it was difficult to harvest from patients under 3 years of age. Woo KI, Kim YD, Kim YH reported satisfactory surgical results were achieved in 78.0% of 82 patients with severe congenital ptosis who underwent frontalis suspension using preserved fascia lata. For patients younger than 2 years of age, preserved fascia lata may be an appropriate substitute for autogenous fascia lata in frontalis suspension surgery.^{1,8}

CONCLUSION

Frontalis Suspension surgery is a way to treat patient with congenital myogenic ptosis who have poor levator function. In this study, using autogenous fascia lata show good results in frontalis suspension surgery. Preserved fascia lata and synthetic materials in frontalis suspension surgery can be tried to know the effectiveness and outcome for treating congenital ptosis with poor levator function.

REFERENCES

1. Skuta GL, Cantor LB, and Wessel JS. Periocular Malpositions and Involutional Changes. In: Orbit, Eyelids, and Lacrimal System. American Academy of Ophthalmology Section 7. San Francisco. 2014-2015. p 201-213.
2. Collin JRO. Ptosis. In: A Manual of Systematic Eyelid Surgery. Third Edition. Elsevier. Butterworth Heinemann. London. 2006. p 85-114.
3. Thapa R, Karmacharya PC, Nepal BP. Etiological pattern of blepharoptosis among patients presenting in teaching hospital. *JNMA J Nepal Med Assoc* 2006;45:218-22.
4. Rizvi SAR, Gupta Y, and Yousuf S. Evaluation of Safety and Efficacy of Silicone Rod in Tarsal Frontalis Sling Surgery for Severe Congenital Ptosis. In: *Ophthal Plast Reconstr Surg* Vol 30, No 1. 2014. p 11-14.
5. Lovine MR. Frontalis Sling for Congenital Ptosis. In: *Manual of Oculoplastic Surgery*. Third Edition. Elsevier. Butterworth Heinemann. Philadelphia. 2003. p 107-112.
6. Betharia SM. Frontalis sling: a modified simple technique. *Br J Ophthalmol* 1985;69:443-5.

7. Crawford JS. Repair of ptosis using frontalis muscle and fascia lata: a 20-year review. *Ophthalmic Surg*1977;8:31-40.
8. Woo KI, Kim YD, and Kim YH. Surgical Treatment of Severe Congenital Ptosis in Patients Younger Than Two Years of Age Using Preserved Fascia Lata. *Am J Ophthalmol* 2014; 157: 1221-1226.
9. Wasserman BN, Sprunger DT, Helveston EM. Comparison of materials used in frontalis suspension. *Arch Ophthalmol*2001;119:687-91.