

# FetalNet

*by* Bambang Tutuko

---

**Submission date:** 02-Jan-2023 10:03AM (UTC+0700)

**Submission ID:** 1987849352

**File name:** FetalNet Low light.pdf (7.22M)

**Word count:** 4978

**Character count:** 26310



ELSEVIER

Contents lists available at ScienceDirect

Informatics in Medicine Unlocked

journal homepage: [www.elsevier.com/locate/imu](http://www.elsevier.com/locate/imu)



1

## FetalNet: Low-light fetal echocardiography enhancement and dense convolutional network classifier for improving heart defect prediction

Sutarno Sutarno<sup>a,b</sup>, Siti Nurmaini<sup>a,\*</sup>, Radiyah Umi Partan<sup>c</sup>, Ade Iriani Sapitri<sup>a</sup>, Bambang Tutuko<sup>a</sup>, Muhammad Naufal Rachmatullah<sup>a</sup>, Annisa Darmawahyuni<sup>a</sup>, Firdaus Firdaus<sup>a</sup>, Nuswil Bernolian<sup>d</sup>, Deny Sulistiyo<sup>a</sup>

<sup>a</sup> Intelligent System Research Group, Faculty of Computer Science, Universitas Sriwijaya, Indonesia

<sup>b</sup> Doctoral Program, Faculty of Engineering, Universitas Sriwijaya, Indonesia

<sup>c</sup> Faculty of Medicine, Universitas Sriwijaya, Indonesia

<sup>d</sup> Division of Fetomaternal, Department of Obstetrics and Gynaecology, Mohammad Hoesin General Hospital, Indonesia



### ARTICLE INFO

2

Keywords:

Deep learning

Ultrasound

Congenital heart disease

Low light image enhancement

### ABSTRACT

2

**Background:** Fetal heart defect (FHD) examination by ultrasound (US) is challenging because it involves low light, contrast, and brightness. Inadequate US images of fetal echocardiography play an important role in the failure to detect FHDs manually. The automatic interpretation of fetal echocardiography was proposed in a previous study. However, the low quality of US images reduces the prediction rate of computer-assisted diagnosis results.

**Methods:** To increase the FHD prediction rate, we propose low-light fetal echocardiography enhancement stacking with a dense convolutional network classifier named "FetalNet." Our proposed FetalNet model was developed using 460 US images to produce an image enhancement model. The results showed that all raw US images could be improved with satisfactory performance in terms of increasing the peak signal-to-noise ratio of 30.85 dB, a structural similarity index of 0.96, and a mean squared error of 18.16. Furthermore, all reconstructed images were used as inputs in a convolutional neural network to generate the best classifier for predicting FHD.

**Results:** The proposed FetalNet model increased the FHD prediction rate by approximately 25% in terms of accuracy, sensitivity, and specificity and produced 100% predictive negative using unseen data.

**Conclusions:** The proposed deep learning model has the potential to identify FHD accurately and shows potential for practical use in identifying congenital heart diseases in the future.

1

### 1. Introduction

Heart defect identification in utero using ultrasound (US) is still frequently missed in prenatal screening, which can result in severe morbidity or even death. Screening programs in most developed countries have reported a detection rate of only 30%–60%, which varies according to the type of cardiac defect and the sonographer's skills [1]. A high volume of standard anomaly scans performed by each sonographer contributes significantly to the prenatal detection rate. Approximately 49% of missed cases are due to a lack of adaptive human skills when performing a standard anomaly scan [2,3]. The quality of US images also appears to play an important role in the success of prenatal

detection of fetal heart defects (FHDs) [2,3]. Inadequate fetal heart US images were significantly more frequent in cases of undetected FHD compared with cases in which FHD was detected [1,3]. However, in 20% of undetected cases, FHDs are not visible, even though US images are of adequate quality [4,5]. Therefore, the quality of US images obtained from fetal heart screening during the second trimester's standard anomaly scan should be improved to potentially increase the FHD detection rate [6].

Prenatal screening most commonly uses a US device to perform imaging modalities, given its non-ionizing radiation, low cost, non-invasiveness, and convenience in use [3,5]. Despite these advantages, there are major challenges to US, such as images having different tissue

4

\* Corresponding author. Intelligent System Research Group, Faculty of Computer Science, Universitas Sriwijaya, Palembang, 30139, Indonesia.

E-mail addresses: [sutarno@unsri.ac.id](mailto:sutarno@unsri.ac.id) (S. Sutarno), [sitinurmaini@gmail.com](mailto:sitinurmaini@gmail.com), [siti\\_nurmaini@unsri.ac.id](mailto:siti_nurmaini@unsri.ac.id) (S. Nurmaini), [radiyati.u.p@fk.unsri.ac.id](mailto:radiyati.u.p@fk.unsri.ac.id) (R.U. Partan), [adeirianisapitri13@gmail.com](mailto:adeirianisapitri13@gmail.com) (A.I. Sapitri), [bambangtutuko60@gmail.com](mailto:bambangtutuko60@gmail.com) (B. Tutuko), [naufalrachmatullah@gmail.com](mailto:naufalrachmatullah@gmail.com) (M. Naufal Rachmatullah), [riset.annisadarmawahyuni@gmail.com](mailto:riset.annisadarmawahyuni@gmail.com) (A. Darmawahyuni), [virdauz@gmail.com](mailto:virdauz@gmail.com) (F. Firdaus), [nuswilbernoli@gmail.com](mailto:nuswilbernoli@gmail.com) (N. Bernolian), [denysulistiyo21@gmail.com](mailto:denysulistiyo21@gmail.com) (D. Sulistiyo).

<https://doi.org/10.1016/j.imu.2022.101136>

Received 19 September 2022; Received in revised form 20 November 2022; Accepted 21 November 2022

Available online 23 November 2022

2352-9148/© 2022 The Author(s). Published by Elsevier Ltd. This is an open access article under the CC BY-NC-ND license (<http://creativecommons.org/licenses/by-nc-nd/4.0/>).

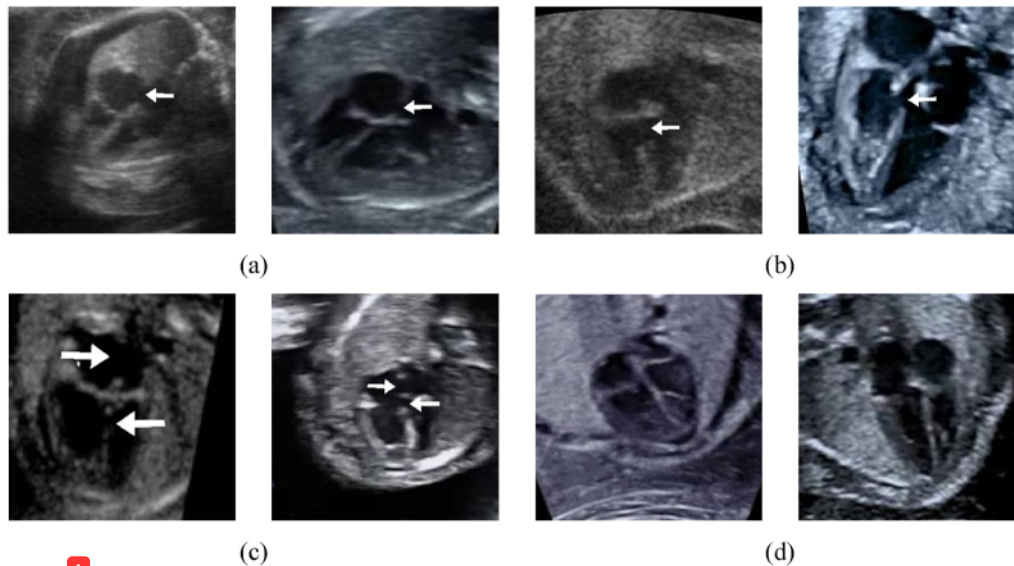
**Table 1**  
Fetal echocardiography data to create FetalNet.

Process	ASD	AVSD	VSD	Normal	total
Training	68	112	68	119	367
Testing	22	28	14	29	93
Unseen	10	10	10	10	40

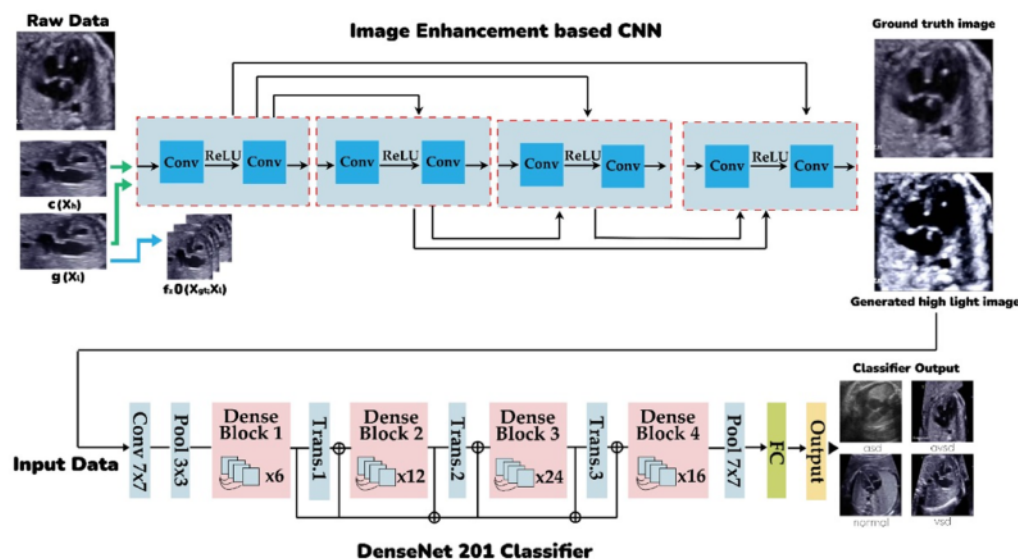
contrast quality where the contrast available is low with imaging artefacts [3–6]. When an image is captured under insufficient light conditions, low contrast, and low brightness, the pixel values are in a low dynamic range, thereby causing the image quality to decrease. Given that the whole echocardiogram appears very dark, it is difficult to

clearly identify heart defects. Low contrast and visibility in US images cause serious effects that can lead to an incorrect diagnosis. Removing these degradations and transforming low-light US images into high-quality, sharp images in fetal echocardiography is helpful to improve the diagnosis and prognosis of FHDs [7,8]. Hence, it is necessary to increase the quality of low-light US images in fetal echocardiography before making a diagnosis.

Low-light image enhancement (LLIE) methods can help increase the brightness, lightness, and contrast of medical images to improve interpretation and visualization [8,9]. Many LLIE methods, mostly based on histogram equalization (HE) techniques [10] and contrast-limited adaptive HE (CLAHE), have been proposed and have achieved great success [11]. They involve a global adjustment process without



**Fig. 1.** Raw fetal echocardiography data showing heart defects: (a) ASD, (b) VSD, (c) AVSD, and (d) normal conditions.



**Fig. 2.** Proposed FetalNet architecture CNN-based low-light image enhancement with a CNN classifier (DenseNet 201).

**Table 2**

CNN-based LLIE model with parameter selection to produce the best model.

Adam optimizer, five layers, input size 300 × 300, reconstructed image size 350 × 250									
Fetal echocardiography	epoch 500			epoch 1000			epoch 2000		
	MSE	SSIM	PSNR	MSE	SSIM	PSNR	MSE	SSIM	PSNR
US 1	22.65	0.96	31.93	19.16	0.97	32.95	18.11	0.97	33.02
US 2	19.02	0.95	31.94	13.91	0.97	32.51	13.74	0.97	33.92
US 3	18.03	0.97	31.73	15.93	0.97	31.79	15.41	0.97	33.21
US 4	29.60	0.91	26.47	25.45	0.93	27.49	25.28	0.93	27.14
US 5	15.01	0.97	30.31	12.59	0.97	29.60	11.72	0.97	30.74
US 6	28.42	0.93	26.28	25.38	0.94	27.18	24.69	0.95	27.15

Adam optimizer, seven layers, input size 250 × 250, reconstructed image 300 × 200									
Fetal echocardiography	epoch 500			epoch 1000			epoch 2000		
	MSE	SSIM	PSNR	MSE	SSIM	PSNR	MSE	SSIM	PSNR
US 1	25.44	0.96	30.35	24.07	0.96	30.98	22.75	0.96	31.46
US 2	19.77	0.96	30.82	17.87	0.97	31.93	16.93	0.97	33.18
US 3	23.84	0.94	28.31	23.39	0.95	28.79	22.39	0.95	29.68
US 4	29.46	0.89	25.27	28.65	0.91	25.49	27.79	0.91	25.27
US 5	18.15	0.97	30.31	16.93	0.97	30.09	17.25	0.97	30.88
US 6	29.32	0.92	24.99	28.31	0.93	25.15	27.33	0.93	25.08

**Table 3**

Benchmarking for three enhancement models.

	CNN model			Retinex-Net model			Autoencoder model		
	MSE	SSIM	PSNR	MSE	SSIM	PSNR	MSE	SSIM	PSNR
US 1	18.12	0.97	33.02	38.51	0.89	27.68	47.77	0.78	24.29
US 2	13.74	0.97	33.92	44.22	0.89	26.55	37.87	0.84	24.57
US 3	15.42	0.97	33.21	42.02	0.89	26.62	37.72	0.84	24.52
US 4	25.28	0.93	27.14	30.12	0.85	26.21	39.15	0.70	21.63
US 5	11.72	0.98	30.75	37.23	0.88	24.15	35.59	0.86	27.36
US 6	24.70	0.95	27.15	34.99	0.85	24.27	37.61	0.72	21.06

considering the change in brightness, which is prone to local over-exposure, color distortion, and poor denoising. These HE methods cause serious color cast problems, and details in darkened areas will not be properly enhanced in many cases [8]. Various image processing methods exist to obtain images with stronger contrast and better brightness; however, all these models produce complex mathematical analysis [8].

The performance of an artificial intelligence (AI)-based medical image analysis system varies significantly with respect to the quality of images with simple algorithms [8,9]. Deep learning (DL)-based models have shown promising performance in various medical imaging modalities [12–18]. In the past few decades, various algorithms have been proposed to vary LLIE performance areas. DL-based convolutional neural networks (CNNs) have achieved great success in LLIE results, image super resolution, and other image-processing applications [12–14,19–21]. CNNs introduce convolutional layers into LLIE and achieve better results in terms of peak signal-to-noise ratio (PSNR) and structural similarity index (SSIM).

Image enhancement models have been proposed to improve natural image quality; however, the reconstructed images obtained in these studies were not processed further. In the current study, reconstructed fetal heart images were further processed in a classifier model. The feed-forward learning approach based on convolutional layers is created to learn low-to-high-resolution mapping and evaluate it on fetal heart images. In summary, this study makes the following contributions:

- Developed a CNN-based LLIE architecture to enhance fetal heart image quality;
- Proposed a stacked architecture, CNN-based LLIE, and CNN-based classifier named “FetalNet” for improving the FHD prediction rate;
- Implemented the FetalNet model to predict three classes of FHD—atrial septal defect (ASD), ventricular septal defect (VSD), and

atrioventricular septal defect (AVSD)—and one class of normal condition; and

- Evaluated the proposed FetalNet model on unseen data to ensure model robustness.

## 2. Material and method

### 2.1. Data preparation

Fetal US videos were taken from General Hospital Muhammad Hoesin, Indonesia. The videos were recorded using a GE Voluson E6 with a loop length of 2–20 s, and the file size was approximately 890 KB to 36.9 MB. The examination was assessed by US after an approximate gestational (menstrual) age of 18–24 weeks. The US videos were retrieved for retrospective analysis using the digital imaging and communications in medicine (DICOM) format. For videos that had been obtained previously, the next step was to convert videos into frames or images and then resizing them to a resolution of 256 × 256 pixels. We used 460 images to develop the FetalNet model with three FHD conditions—ASD, VSD, and AVSD—and normal conditions (Table 1). The learning process was conducted without data augmentation to maintain the actual clinical condition. To prove the heart defect model’s robustness, we used two scenarios based on intra- and inter-patient (unseen) data.

An increased depth indicates that a lower frequency is required for optimal imaging. Consequently, the images have a lower resolution. Over time, US machines have become more sophisticated, some of which use the returning second-degree harmonic of the original frequency to produce an improved image. However, they still produce low levels of lightness, contrast, and brightness. Good image quality is fairly subjective and is also relative to the capabilities of the US machine. Samples of raw US images on fetal echocardiography are depicted in Fig. 1. However, wall-chamber boundaries are difficult to see, particularly on

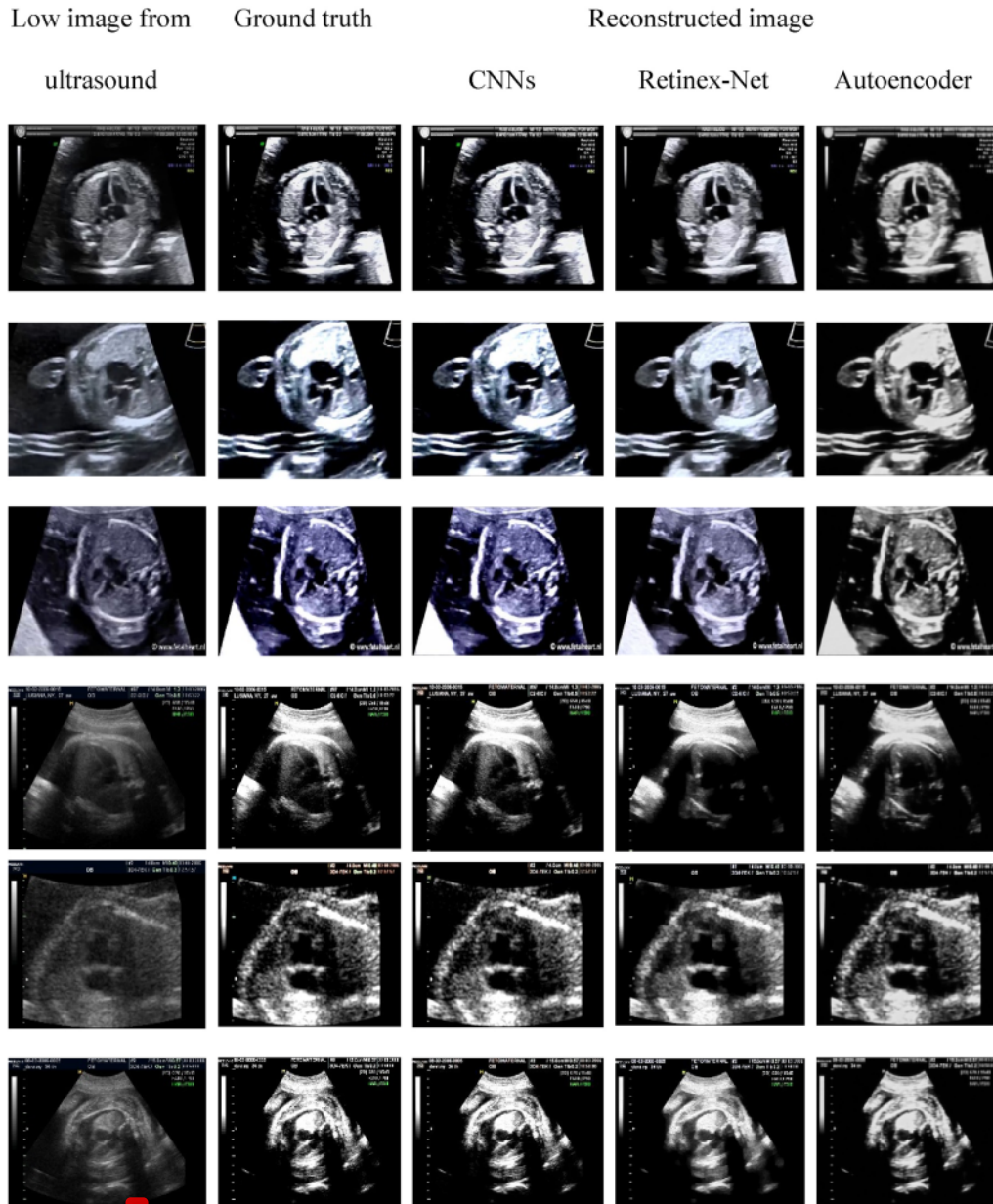


Fig. 3. Sample of a reconstructed image with three architectures: CNNs, Retinex-Net, and Autoencoder.

1

Table 4

Performance comparison with other LLIE models based on DL.

Model	Implementation	PSNR	SSIM	MSE
Super resolution CNN [20]	Brain image	37.02	0.97	-
Deep convolutional network [21]	Natural image	-	0.92	-
Deep Autoencoder [24]	Natural image	24.27	0.61	-
Super resolution CNN [25]	Remote sensing image	28.19	0.83	-
Proposed CNN-based LLIE	Fetal echocardiography	30.87	0.96	18.16

1

difficult-to-image patients with much “noise” in the image.

Accordingly, LLIE, as a pre-processing step, is of significance and also desired before predicting heart defects. The main difficulty in modeling LLIE on fetal echocardiography is how to collect a set of training data. Such a process relies on low- and high-resolution image pairs to train a network in a fully supervised manner. Unfortunately, such image pairs are unavailable in real-world applications, or the ground truth is unknown. Therefore, we manually adjusted the contrast and brightness of low-light US images using software at the upper and lower threshold values for each pixel intensity [22]. By using such techniques, high-quality fetal echocardiography was created as the ground truth.

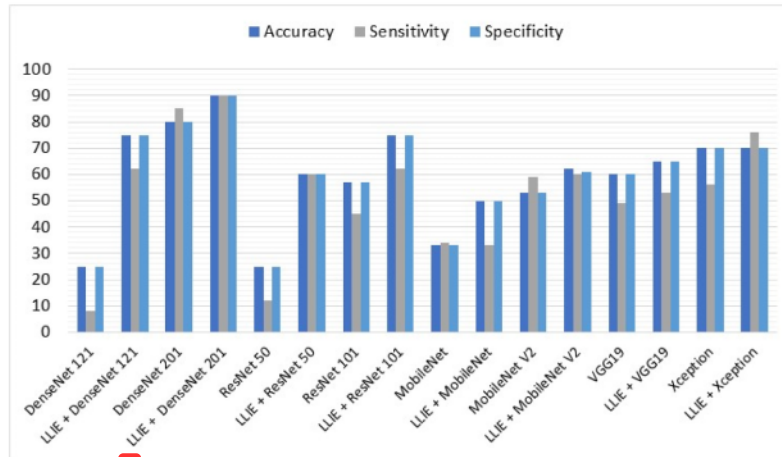


Fig. 4. FetalNet model with eight classifiers' architecture with unseen data.

1

## 2.2. FetalNet architecture

The FetalNet model is an extension of LLIE with a predicted model of a CNN classifier architecture. Our previous studies without the LLIE model failed to predict FHD in unseen data [17]. However, this model successfully predicted the wall chamber and aorta only under normal conditions. To improve the FHD prediction rate, we developed the FetalNet model in this study. The general methodology is depicted in Fig. 2 and summarized as follows:

- Fetal echocardiography image enhancement was developed based on a CNN-based LLIE model. Such architecture consisted of a convolution layer as an input, a convolutional module for multiscale learning feature maps to produce an enhanced image, and a convolution layer as an output. The convolution input layer was used to generate uniform input data. The reconstruction module was used to learn the raw image with different kernels to improve the image quality in accordance with the image target that was prepared. The output layer was fused with the feature map to generate the reconstructed image.
- The LLIE learning process used deep inception and residual networks adopted from a previous study [16] or <https://github.com/BestJully/LLCNN>. However, in the current study, we simplified the architecture with one layer of input data, five layers of reconstruction modules, and one layer of output data.
- The raw image size and the reconstructed image size were approximately  $256 \times 256$  pixels. To increase US image quality, we used SSIM loss as the objective function of the LLIE network. SSIM loss is denoted by  $1 - SSIM(p)$ , where  $SSIM(p)$  is the SSIM that measures pixel  $p$ , which is explained in Ref. [16]. The learning rate was approximately  $2 \times 10^{-4}$  with an Adam optimizer. A batch size ranging from 8 to 32 was used with epochs ranging from 500 to 2000 with an early stopping mechanism.
- To achieve outstanding performance, the high-quality US image target should have a PSNR value close to 35 dB and an SSIM value close to 1. We benchmarked three LLIE backbones—CNNs, Retinex-Net [23], and deep autoencoder [24]—to ensure the enhancement of the image quality performance.
- The output of the LLIE model was a reconstructed image used as an input into the CNN classifier to predict FHDs. Eight CNN architectures (ResNet 50, ResNet 121, DenseNet 102, DenseNet 201, VGG 19, Xception, MobileNet, and MobileNetV2) were compared to select the best FetalNet model evaluated only in unseen data.

All of the networks were implemented using Python and the Pytorch 1.7.1 library and trained using a computer with the following specifications: Intel® Core™ i9-9920X CPU @ 3.50 GHz processor with 490,191 MB RAM, GeForce 2080 RTX Ti by NVIDIA Corporation GV102 (rev a1), and an Ubuntu 18.04.5 LTS operating system.

## 3. Result and discussion

This section addresses various experiments to demonstrate the effectiveness of our approach. Comparisons with other methods are also presented. Three LLIE backbone architectures were created (CNNs, Retinex-Net, and Autoencoder) to enhance fetal echocardiography image quality. Eight CNN classifiers were developed to increase the FHD prediction rate.

### 3.1. CNN-based LLIE model performance

The PSNR value approaches infinity as the mean square error approaches zero. This shows that a higher PSNR value provides a higher enhancement. At the other end of the scale, a small PSNR value implies high numerical differences between the images. SSIM is a well-known quality metric used to measure the similarity between two images. It is designed by modeling any image distortion as a combination of the following three factors: loss of correlation, luminance distortion, and contrast distortion. The positive values of the SSIM index are in  $[0,1]$ . A value of 1 indicates a high correlation between the image and vice versa. Table 2 shows that our proposed model with 2000 epochs produced good performance with PSNR from 27 dB to 33 dB and an SSIM from 0.93 to 0.91 (close to 1). This means that the a high correlation was reached between the target and the reconstructed images.

Two CNN-based LLIE architectures were created based on five and seven convolutional block layers to achieve the best enhancement model (Table 2). The experimental results showed that the best LLIE architectures had an input size of  $300 \times 300$ , a reconstructed size of  $350 \times 250$ , a batch size of 8, and a learning rate of 0.0001. The model used an Adam optimization function with five convolutional block layers and learning processes run on epoch 2000.

To verify our selected CNN-based LLIE model's effectiveness and robustness, we benchmarked using the Retinex-Net model [23] and the Autoencoder model [23]. The enhancement performance was compared in terms of the MSE, SSIM, and PSNR. The results showed that the proposed LLIE outperformed state-of-the-art models. Such a model produced a high PSNR from 27.14 dB to 33 dB, all SSIMs of over 93%,

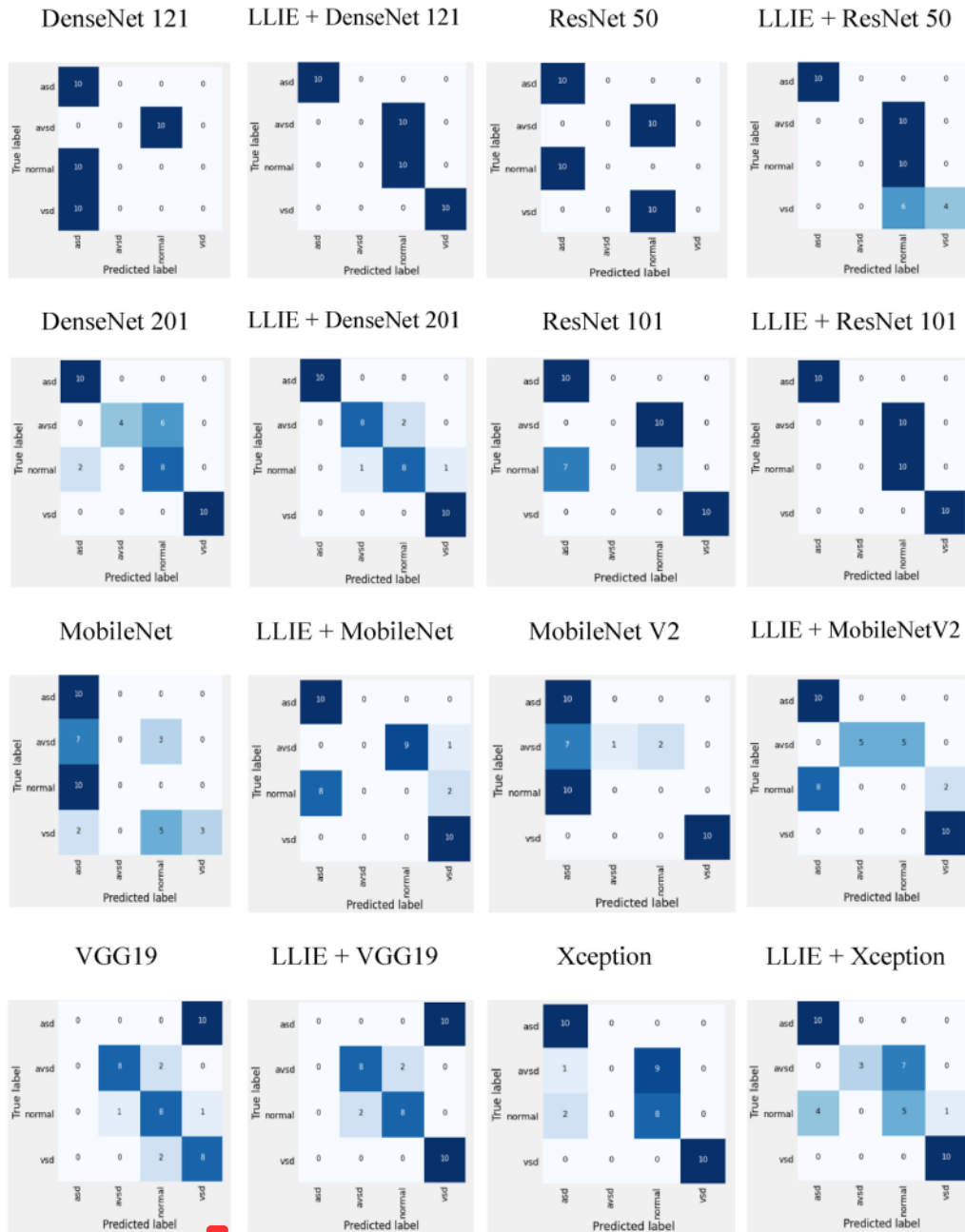


Fig. 5. Confusion matrix FHD prediction with and without LLIE in unseen data.

and all MSEs performed under 25% for six fetal heart US videos. All metrics show that our LLIE performance achieved satisfactory results (Table 3). This indicates that the error between the ground truth and the reconstructed image was low. Our model produced an MSE of approximately 18.16, implying that the reconstructed image had been properly restored. Furthermore, the quality of the restored image was improved. Using the CNN-based LLIE reaches an SSIM of a reconstructed image to a ground-truth image close to 1, indicating that the US image was improved.

A sample of a reconstructed image using three LLIE architectures is depicted in Fig. 3. Low fetal echocardiogram, as raw data from an US, had lower lightness, brightness, and contrast. Ground truth data are unavailable in real-world settings. We used layers in Python to manually enhance fetal echocardiography to generate artificial, corresponding ground truth images. By using brightness and contrast adjustment [22] techniques, we improved fetal echocardiography at the upper and lower threshold values for each pixel intensity. We made a fair comparison with other DL architectures: Retinex-Net and the Autoencoder model.

The LLIE in fetal echocardiography was an important process because low-quality images can reduce the prediction rate. With CNN-based LLIE, the quality can be improved in these three parameters. However, the DL-based LLIE method has limited medical applications, as found in the previous study. We benchmarked our proposed LLIE model with state-of-the-art models in a low-light image application [20,21,24,25] (Table 4). The proposed CNN-based LLIE architecture achieved better performance based on learning to map directly from low-to high-quality images, with 30.87 dB PSNR, 0.96 SSIM, and 18.16 MSE. This means that our model could enhance the lightness, brightness, and contrast of fetal echocardiography.

### 3.2. FetalNet prediction performance

In this study, reconstructed images from the LLIE model were used to predict FHDs. The model performance was considered successful or unsuccessful in classifying four classes (ASD, VSD, AVSD, and normal). To ensure that the developed model was reliable, we used eight CNN architectures: Densenet 121, DenseNet 201, ResNet 50, ResNet 101, MobileNet, MobileNetV2, VGG19, and Xception. Based on the quantitative analysis indicators, FetalNet with DenseNet 201 architecture produced better improvement than other CNN architectures. As shown in Figs. 4 and 5, the whole architecture could obtain classification tasks from images' enhancements. However, the results of many methods were not sufficient or satisfactory, especially in terms of specificity.

Based on the experiments, FetalNet architectures produce satisfactory performances of approximately 90% in sensitivity, specificity, and accuracy. With a confusion matrix, FetalNet was evaluated for four classes: ASD, VSD, AVSD, and normal condition. DenseNet 201 produced a 100% predictive negative, whereas the proposed model could predict all normal conditions (Fig. 5). All FHD conditions were successfully predicted with unseen data, even for AVSD, and FetalNet with DenseNet 201 improved the prediction rate by 7%–10%.

An end-to-end FetalNet model was proposed to obtain reconstructed fetal echocardiography images from degraded low-light images. The model was applied to classify the four classes of FHD. The limitation of our proposed model was the limited number of fetal echocardiography US images, and the unseen data only included eight videos. Nevertheless, the amount of data was sufficient for neural networks in general. Therefore, the results were likely not significantly affected by the number of individual fetuses. The CNN-based LLIE shows potential for use in improving the quality of low-resolution and low-light images of fetal echocardiography. Furthermore, our proposed model typically requires only a few seconds for LLIE, thereby supporting US device inline reconstruction for clinical applications.

## 4. Conclusion

Despite advancements in US imaging, the prenatal identification of FHDs is still low, based on population studies. The complex anatomy of the fetal heart, along with its small size and the diverse nature of fetal heart abnormality, adds to the examination's complexity. In addition, the operator's dependency on US, along with the variable position of the fetus within the abdomen, results in a lack of standardization, consistency, and reproducibility. The fetal heart is very small, and US examinations need to pass through the maternal and fetal bodies, causing higher noise and lower contrast in the images, making the examination and diagnosis a challenge for even the most experienced physicians. Hence, the enhancement of image quality is an important process to improve reproducibility and consistency in fetal heart evaluation. We proposed FetalNet for increasing image quality and FHD prediction automatically based on obstetric and gynecology practices. Our results show that our proposed model has the ability to improve the FHD prediction rate by 70% for new patients (unseen). We believe that fetal heart examination using the DL technique will hopefully result in the reproducibility and consistency of fetal echocardiography.

## Ethics approval and consent to participate

All methods were carried out in accordance with relevant guidelines and regulations. All experimental protocols were approved by General Hospital Muhammad Hoesin, Indonesia Ethics Committee (approval no. 18/kepkrsmh/2022) and informed consents was obtained from all subjects and/or their legal guardians.

## Consent for publication

Written informed consent was obtained from all the participants for publish the data in open access journal.

## Availability of data and materials

The code is available in <https://github.com/BestJuly/LLCNN>, while the dataset is available in <https://github.com/ISySRGg/LLCNNs>.

## Funding

This study was funded by "Hibah Doktor Research" from the Ministry of Education, Culture, Research, and Technology, Indonesia, and under Profesional Grants by Universitas Sriwijaya.

## Author's contribution

S.S. Conceptualization, Conceived and designed the analysis. S.N. Wrote the manuscript, Data Curation, Investigation and Funding acquisition. N.B and R.U.P. Medical Verification. A.I.S. Data Curation. Performed the analysis, Formal Analysis and Methodology. B.T. Resources and Data Curation. M.N.R. Contributed data or analysis tools and Resources. A.D. Resources and Visualization Preparation. F.F. Resources and Data Curation. D.S. Data Curation. Performed the analysis and Formal Analysis.

## Declaration of competing interest

The authors declare that they have no known competing financial interests or personal relationships that could have appeared to influence the work reported in this paper.

## Acknowledgement

We thank the Intelligent System Research Group (ISysRG) Universitas Sriwijaya, Indonesia, for their full support of research infrastructure.

## References

- [1] van Nesselrooij AEL, et al. Why are congenital heart defects being missed? *Ultrasound Obstet Gynecol* 2020;55(6):747–57. <https://doi.org/10.1002/uog.20358>.
- [2] Donofrio MT, et al. Diagnosis and treatment of fetal cardiac disease: a scientific statement from the American heart association. *Circulation* 2014;129(21):2183–242. <https://doi.org/10.1161/01.cir.0000437597.44550.5d>.
- [3] Bak GS, et al. Detection of fetal cardiac anomalies: cost-effectiveness of increased number of cardiac views. *Ultrasound Obstet Gynecol* 2020;55(6):758–67. <https://doi.org/10.1002/uog.21977>.
- [4] Sekar P, Heydarian HC, Cnota JF, Homberger LK, Michelfelder EC. Diagnosis of congenital heart disease in an era of universal prenatal ultrasound screening in southwest Ohio. *Cardiol Young* 2015;25(1):35–41. <https://doi.org/10.1017/S1047951113001467>.
- [5] Chakraborty A, Gorla SR, Swaminathan S. Impact of prenatal diagnosis of complex congenital heart disease on neonatal and infant morbidity and mortality. *Prenat Diagn Nov.* 2018;38(12):958–63. <https://doi.org/10.1002/pd.5351>.
- [6] Chauvi R, Abuhamad A, Martins J, Heling KS. Recent development in three and four dimension fetal echocardiography. *Fetal Diagn Ther* 2020;47(5):345–53. <https://doi.org/10.1159/000500454>.
- [7] Gudigar A, et al. Role of four-chamber heart ultrasound images in automatic assessment of fetal heart: a systematic understanding. *Informatics* 2022;9(2). <https://doi.org/10.3390/informatics9020034>.



- [8] Liu S, et al. Deep learning in medical ultrasound analysis: a review. *Engineering* 2019;5(2):261–75. <https://doi.org/10.1016/j.eng.2018.11.020>.
- [9] Alsharqi M, Woodward WJ, Mumith JA, Markham DC, Upton R, Leeson P. Artificial intelligence and echocardiography. *Echo Res. Pract.* 2018;5(4):R115–25. <https://doi.org/10.1530/ERP-18-0056>.
- [10] Yamashita K, Markov K. Medical image enhancement using super resolution methods BT - computational science – ICSCS 2020. 2020. p. 496–508.
- [11] Yoo JS, Choi JH, Choi KS, Lee DY, Kim HY, Kim JO. Contrast limited adaptive histogram equalization image processing to improve the detection of simulated spiculations in dense mammograms. *IEICE Trans Info Syst* 2016;E99D(8):2194–8. <https://doi.org/10.1587/transinf.2016EDL8049>.
- [12] Nasrin S, Alom MZ, Burada R, Taha TM, Asari VK. Medical image denoising with recurrent residual U-net (R2U-net) base auto-encoder. In: 2019 IEEE national aerospace and electronics conference. (NAECON); 2019. p. 345–50. <https://doi.org/10.1109/NAECON46414.2019.9057834>.
- [13] Berggren K, Ryd D, Heiberg E, Aletras AH, Hedström E. Super-resolution cine image enhancement for fetal cardiac magnetic resonance imaging. *J Magn Reson Imag* 2022;56(1):223–31.
- [14] Li C, Guo J, Porikli F, Pang Y. LightenNet: a Convolutional Neural Network for weakly illuminated image enhancement. *Pattern Recogn Lett* 2018;104:15–22. <https://doi.org/10.1016/j.patrec.2018.01.010>.
- [15] Yang W, Zhang X, Tian Y, Wang W, Xue J-H, Liao Q. Deep learning for single image super-resolution: a brief review. *IEEE Trans Multimed* 2019;21(12):3106–21.
- [16] Tao L, Zhu C, Xiang G, Li Y, Jia H, Xie X. LLCNN: a convolutional neural network for low-light image enhancement. In: 2017 IEEE visual communications and image processing. VCIP; 2017. p. 1–4. <https://doi.org/10.1109/VCIP.2017.8305143>.
- [17] Nurmaini S, et al. Accurate detection of septal defects with fetal ultrasonography images using deep learning-based multiclass instance segmentation. *IEEE Access* 2020;8:196160–74. <https://doi.org/10.1109/ACCESS.2020.3034367>.
- [18] Qiao S, et al. RLDS: an explainable residual learning diagnosis system for fetal congenital heart disease. *Future Generat Comput Syst Mar.* 2022;128:205–18. <https://doi.org/10.1016/j.future.2021.10.001>.
- [19] Nurmaini S, et al. Deep learning-based computer-aided fetal echocardiography: application to heart standard view segmentation for congenital heart defects detection. *Sensors* 2021;21(23). <https://doi.org/10.3390/s21238007>.
- [20] Qiu T, Wen C, Xie K, Wen FQ, Sheng GQ, Tang XG. Efficient medical image enhancement based on CNN-FBB model. *IET Image Process* 2019;13(10):1736–44. <https://doi.org/10.1049/iet-ipr.2018.6380>.
- [21] Shen L, Yue Z, Feng F, Chen Q, Liu S, Ma J. MSR-net:Low-light image enhancement using deep convolutional network. November; 2017.
- [22] Kim EK, Lee H, Kim S, Cho H. Automatic brightness adjustment system by fuzzy inference system for object recognition. In: 2017 joint 17th world congress of international fuzzy systems association and 9th international conference on soft computing and intelligent systems. IFSA-SCIS; 2017. p. 1–6. <https://doi.org/10.1109/IFSA-SCIS.2017.8023340>.
- [23] Zhong D, Huabao and fan, zhang and Xie, Liyin and Bin, Xu and Wang, Junliang and Liu, Guijun and Lin, “feature based deep Retinex for low-light image enhancement. In: 2020 4th international conference on advances in image processing; 2020. p. 66–71.
- [24] Lore KG, Akintayo A, Sarkar S. LLNet: a deep autoencoder approach to natural low-light image enhancement. *Pattern Recogn* 2017;61:650–62. <https://doi.org/10.1016/j.patcog.2016.06.008>.
- [25] Images R, Hu L, Qin M, Zhang F, Du Z, Liu R. Rscnn : a CNN-based method to enhance low-light. 2021. p. 1–13.

# FetalNet

## ORIGINALITY REPORT

85%

SIMILARITY INDEX

21%

INTERNET SOURCES

83%

PUBLICATIONS

10%

STUDENT PAPERS

## PRIMARY SOURCES

1	Sutarno Sutarno, Siti Nurmaini, Radiyati Umi Partan, Ade Iriani Sapitri et al. "FetalNet: Low-light fetal echocardiography enhancement and dense convolutional network classifier for improving heart defect prediction", Informatics in Medicine Unlocked, 2022 Publication	76%
2	doaj.org Internet Source	6%
3	Submitted to North Harris Montgomery Community College District Student Paper	2%
4	Submitted to Sriwijaya University Student Paper	1%
5	eprints.lums.ac.ir Internet Source	1%

Exclude quotes  On

Exclude matches  < 1%

Exclude bibliography  On

